Original Article

Surgical Outcome of Transcranial Intradural Repair in Post Traumatic Cerebrospinal Fluid Leak

Samina Khaleeq*
Muhammad Khalid**
Khaleeq UZ Zaman**

**Associate Professor*
***Postgraduate Resident*
****Professor and Head of Dept.*
Department of neurosurgery, Pakistan Institute of Medical Sciences, Shaheed Zulfiqar Ali Bhutto Medical University, Islamabad, Pakistan.

ABSTRACT

Objective: To study the outcome of Transcranial repair in post traumatic CSF leak in head injury patients

Study Design: Prospectively Study

Place and Duration: From May 2013 to May 2015 at Pakistan Institute of Medical Sciences, Islamabad.

Materials and Methods: All patients who have CSF leak after head injury were included in this study. All cases were studied prospectively at our center during period of 2 years. Patient's demographic profiles, symptoms and signs, imaging studies, complications and outcome were assessed prospectively. The mean age of patients was 26.20 years, male /female ratio was 72:20, 76 out of 92 were adult and 16 were children.

MRI images were used to identify the accurate site of dural rent which is very essential for successful result. Transcranial intradural repair was done in all patients whom dural rent was confirmed on MR images.

Results: A total of 92 cases were studied prospectively, all patients were started on prophylactic antibiotics and observed for 72 hours. Patients mostly presented with loss of consciousness, vomiting, nasal or ear bleed, fits and severe headache.

In 44 patients CSF leak stopped spontaneously. In 48 patients MRI brain especially T2 images coronal cuts in prone position was done to define the accurate site of CSF leak. 38 out of 48 patients improved (79.16%), 3 patients died (6.25%) and 5 patients still had leak after repair and lumber drain insertion (10.41%) that were reopened.

Conclusion: The Transcranial repair (duraplasty) for post traumatic CSF leak is highly effective with good results.

Keywords: Trans Crainal, Intradural repair, Post traumatic, CSF Leak, MRI Finding.

Address for Correspondence
Dr. Muhammad Khalid
Postgraduate Resident
Department of neurosurgery, Pakistan Institute of Medical Sciences, Shaheed Zulfiqar Ali Bhutto Medical University, Islamabad
Email: drkhalid86@yahoo.com

Introduction

Cerebral spinal fluid leak results when the fluid around the brain leaks through a hole in dura and the skull bone. This fluid can either drain from the ear or the nose, depending on where the skull bone is damaged.[1] Mostly Patients complain of watery discharge from one side of the nose or one ear. Watery Discharge can increase with tilting the head forward. Patients can present with headache, hearing loss and anosmia.[2-4] There are two types of CSF leak, one is spontaneous and other one is traumatic CSF leak. Etiology of CSF leak is congenital, developmental, sella turcica anomalies, hydrocephalus, tumors, surgery for base of skull and infections.[1-4] The most common cause of CSF leak is trauma, especially trauma to the frontal region.[4, 5] The incidences of CSF leak in closed

head injury patients are 3% and in skull base fracture is 30 %. [5-8] Post traumatic CSF leak can present either as CSF Rhinorrhea or Otorrhea[9, 10]. Management of CSF leak can be either medical or surgical. Conservative management is recommended first in cases of spontaneous CSF leak or head trauma. Different approaches and techniques are used for repair of CSF leak. One of them is trans nasal endoscopic repair and other one is trans cranial repair for CSF leak in head injury patients especially in those CSF leak which is secondary to anterior skull base fractures.[11-22]

The identification of accurate site of CSF leak is very important for successful results so we need special cuts of brain MRI in full prone position to identify the dural rent.[23- 25] We treated the post traumatic CSF leak through Trancranial repair.

The authors report their experience in the outcome while managing the post traumatic CSF leak with Tran cranial approach with confirmation of dural rent on MRI.

Materials and Methods

The authors came across with CSF leak in head injury patients of different variety. All patients were studied prospectively at our center during the period of two years. Mostly patients were young males with mean age of 26 years. All patients were started on conservative treatment and observed for 48 to 72 hours. Conservative treatment means bed rest, serial lumber punctures and subarachnoid lumber drains. Those patients who had nose or Ear bleed, raccoon eyes, battle sign and Anosmia on examination, were observed for CSF leak. CSF leak presented in the form of rinorrhea or otorrhea. CT scan brain was done in all patients. CT scan revealed gross pneumocephalus in all patients with hazy sinuses in 30 %. In 50 % patients CSF leak were stopped in first week of trauma. MRI brain especialy T2 images coronal cuts in prone position was done in all patients with persistent rinorrhea to see an accurate site of Dural rent which is very essential for successful results. After identification of dural rent on MRI brain, patients were prepared for craniotomy plus duraplasty. Different kinds of grafts are used for duraplasty. We used fascia lata graft for dural repair. The lumber drain was used in those patients in whom dural rent was extended up to middle fossa.

All patients were studied carefully, 48 patients out of 92 were treated with craniotomy plus duraplasty and 44 patients were treated conservatively.

Results

Total 92 cases were studied prospectively at our center during period of 2 years from May 2013 to May 2015. All patients were started on prophylactic antibiotics and observed for 72 hours. In 44 patients out of total 92, CSF leak stopped spontaneously and 48 patients were treated by craniotomy plus duraplasty. MRI brain was done in all 48 cases to define the accurate site of CSF leak. In 5 patients fracture line was extending into middle fossa so post operatively lumber drain was put for 7 days. In 38 patients out of 48, CSF leak stopped (79.16%) after duraplasty, 3 patients died (6.25%) and 5 patients had leak post operatively (10.41%) who had extensive compound depressed in frontal region involving frontal sinus. Patients, in whom CSF leak did not stop with lumber drain, were reopened.

Complications developed in 10 cases (20.83) out of 48 cases. Meningitis developed in four patients (8.33%), Pneumocephalus occurred in four patients, Hydrocephalus developed in one patient (2.08%) which was VP shunted later on and brain abscess in one patient (2.08%).

Out of those three patients, one patient died due to meningitis and cerebritis, second patient developed brain abscess which was excised but patient did not survive, last patient had multiple dural rents and post operatively he developed tension pneuemocephalus, for which tap was done but patient did not survive .

Out of 48 patients, 38 had excellent recovery who underwent transcranial duraplasty.

In our series we studied 92 patients prospectively in two years duration. Mostly they were young males and mode of trauma was road traffic accidents. 80%

patients developed Cerebrospinal fluid leak who had nose or ear bleed, raccoon eyes or battle sign, and peunomocephalus on CT scan after trauma (table no. I).

Table no I. Common presentation of CSF leak patients

S. No	symptom	Percentage	sign	Percentage
1	Headache	60 to 70 %	Raccoon eyes	70 to 80%
2	vomiting	20 to 40 %	Battle sign	60 to 70 %
3	Nose or ear bleeding	65 to 75 %	Anosmia	65 to 75 %
4	Loss of consciousness	30 to 45%		
5	Fits	15 to 35 %		

All patients were started on prophylactic antibiotics and observed for 72 hr. In 44 patients CSF leak stopped spontaneously and they were treated conservatively and no CSF leak was reported in follow up. Rest 48 patients were further investigated by doing MRI brain, in which dural rent was identified and repair was done within 2 weeks by transcranial intradural approach. CT scan and MRI brain pictures of some of the patients are. (Figure no. 1, 2, 3, 4)

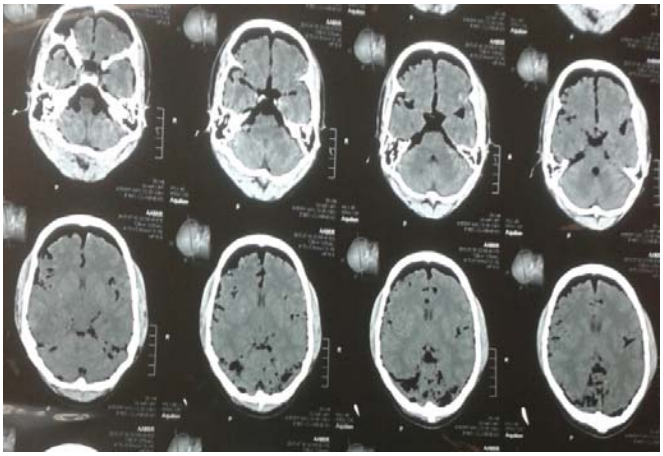

Figure no.1 CT scan brain revealed Gross Pnuemocephalus

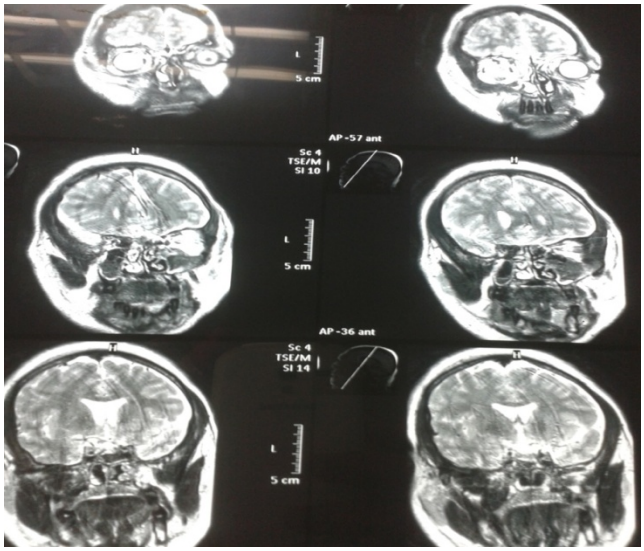

Figure no.2 MRI brain coronal cuts T2 images revealed Dural rent right side

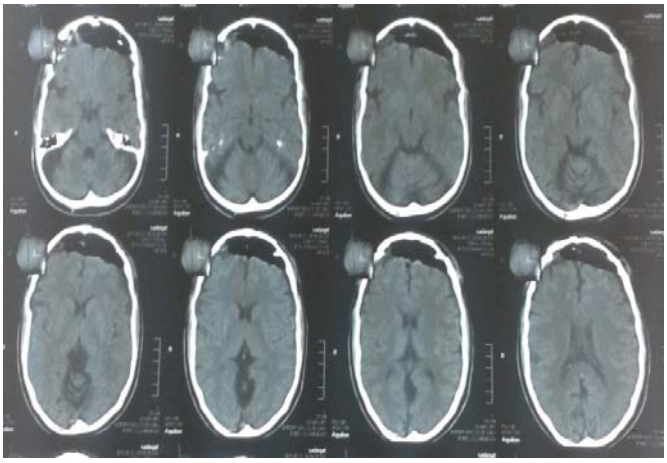

Figure no. 3 .CT scan Brain showed Pneumocephalus

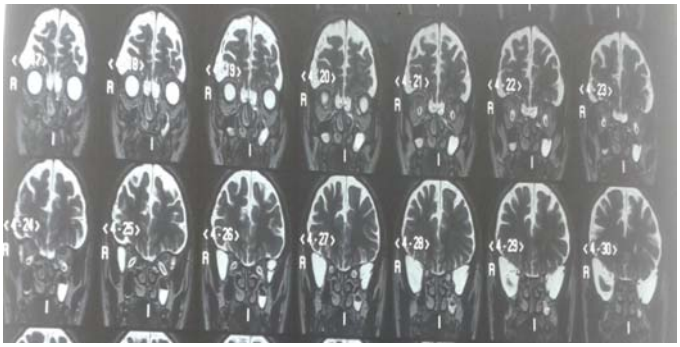

Figure no .4 MRI Brain coronal cuts T2 images revealed bilateral Dural rent

Discussion

Literature review shows a lot of discussion on Cerebrospinal fluid leak, its causes, presentation, outcome, Complication and management.[1-8] Different authors have different opinions for its management.[9, 10]

Different approaches are used for repair which include Transcranial approach (intracranial extradural repair and intracranial intradural repair) and transnasal endoscopic approach.[11-18] During repair different kinds of grafts are used.[17-20]

The most common cause of cerebrospinal fluid leak is trauma that presents in form of rinorrhea or otorrhea. Frontal bone fractures mostly present with rhinorrha, and temporal bone fractures present with otorrhea.[19, 20]

Mostly authors agree with conservative management initially that includes bed rest, serial lumber puncture, subarachnoid lumber drains and medication.[21]

Those Patients who presented with nose or ear bleed , raccoon eyes, battle sign and pneuomocephalus on CT scan have more than 70% chances to develop cerebrospinal fluid leak.[22]

All patients who develop cerebrospinal fluid leak after trauma need further investigations. Most reliable one is MRI brain especially T2 images coronal cuts in prone position to identify the accurate site of CSF leak. For successful results dural rent identification is very important.[23-25]

In those cases where the fracture was extensive and reached middle fossa, postoperatively lumber drain was putt to prevent leak and further complications, but there are chances of meningitis after lumber drain insertion which developed in four patients in our series. There are rare chances of Hydrocephalus and pneumocephalus postoperatively.[14]

The authors report that post traumatic CSF leak need dural repair when the accurate site of dural rent is identified on MR images, either by transcranial or transnasal endoscopic approach depending upon the expertise.

Conclusion

In this study the authors concluded that Transcranial repair (duraplasty) for post traumatic CSF leak is highly effective with good results must be done as early as possible in those patients in whom Dural rent is identified on MR images.

References

1 Jonathan A. Friedman, Michael J. Ebersold, Lynn M. Quast. Post-traumatic Cerebrospinal Fluid Leakage. World Journal of Surgery August 2001; Volume 25, Issue 8, pp 1062-1066.

2 Kainz J, Stammberger H. The roof of the anterior ethmoid: a place of least resistance in the skull base. *Am J Rhinol* 1989;3:191–199

3 Carrau RL, Snyderman CH, Janecka IP, Sekhar L, Sen C. Role of antibiotic prophylaxis in cranial base surgery. *Head Neck Surg*1991; 13(4):311–317.

4 Dagi FT, George ED. Management of cerebrospinal fluid leaks. In: SchmidekHH, SweetWH, eds. *Operative Neurosurgical Techniques: Indications, Methods and Results*. Orlando, FL: Grune & Stratton, 1988:49–69.

5 Ricardo L. Carrau MD Carl H. Snyderman MD Amin B. Kassam MD. The Management of Cerebrospinal Fluid Leaks in Patients at Risk for High-Pressure Hydrocephalus. The Laryngoscope February 2005: Volume 115, Issue 2, pages 205–212.

6 M.N.H. Lloyd, P.M. Kimber E.H. Burrows. Post-traumatic cerebrospinal fluid rhinorrhoea: Modern high-definition computed tomography is all that is required for the effective demonstration of the site of leakage. Clinical Radiology february1994: volume 49, Issue 2, Pages 100-103

7 Bell RB[1], Dierks EJ, Homer L, Potter BE. Management of cerebrospinal fluid leak associated with craniomaxillofacial trauma. J Oral Maxillofac Surg. 2004 Jun;62(6):676-84.

8 Schoentgen C, Henaux PL, Godey B, Jegoux F. Management of post-traumatic cerebrospinal fluid (CSF) leak of anterior skull base: 10 years experience. Acta Otolaryngol. 2013 Sep;133(9):944-50. doi: 10.3109/00016489.2013.793821.

9 Mantur M, Łukaszewicz-Zając M, Mroczko B, Kułakowska A, Ganslandt O, Kemona H, Szmitkowski M, Drozdowski W, Zimmermann R, Kornhuber J, Lewczuk P. Cerebrospinal fluid leakage--reliable diagnostic methods.Clin Chim Acta. 2011 May 12; 412(11-12):837-40. doi: 10.1016/j.cca.2011.02.017. Epub 2011 Feb 17. Review

10 Scholsem M, Scholtes F, Collignon F, Robe P, Dubuisson A, Kaschten B, Lenelle J, Martin D. experience. Neurosurgery. 2008 Feb;62(2):463-9; discussion 469-71. doi: 10.1227/01.neu.0000316014.97926.82.

11 Okuda T, Kataoka K, Kitano M, Watanabe A, Taneda M. Successful treatment of a patient with a 13-year history of post-traumatic rhinorrhea due to malabsorption of cerebrospinal fluid.Minim Invasive Neurosurg. 2005 Aug;48(4):247-9.

12 Bernal-Sprekelsen M, Bleda-Vázquez C, Carrau RL. Ascending meningitis secondary to traumatic cerebrospinal fluid leaks. Am J Rhinol. 2000 Jul-Aug;14(4):257-9.

13 Nallet E, Decq P, Bezzo A, Le Lievre G, Peynegre R, Coste A. Endonasal endoscopic surgery in the treatment of spontaneous or post-traumatic cerebrospinal fluid (csf) leaks.Ann Otolaryngol Chir Cervicofac. 1998 Oct;115(4):222-7. French.

14 Sahar A, Beller AJ, Feinsod M. Increased intracranial pressure in post-traumatic rhinorrhoea.Neurochirurgia (Stuttg). 1982 Sep;25(5):170-3.

15 Sen A. Idiopathic intracranial hypertension presenting solely as CSF rhinorrhea. J Neurosurg. 2014 Sep;121(3):765-6. doi: 10.3171/2012.7.JNS12665. Epub 2014 Jul 18.

16 Vaphiades MS, Ranganath NK, Woodworth BA. Spontaneous cerebrospinal fluid otorrhea and rhinorrhea in idiopathic intracranial hypertension patients.J Neuroophthalmol. 2013 Dec;33(4):416. doi: 10.1097/WNO.0000000000000061

17 Rodríguez de Antonio LA, Tallón Barranco A, Díez-Tejedor E. CSF fistula in a woman with a history of idiopathic intracranial hypertension].Neurologia. 2010 Oct;25(8):515-6. Spanish.

18 Discharge of cerebrospinal fluid through the nose. Common etiologies include trauma, neoplasms, and prior surgery, although the condition may occur spontaneously. (Otolaryngol Head Neck Surg 1997 Apr;116(4):442-9

19 Lloyd, K. M.; Delgaudio, J. M.; Hudgins, P. A. (2008). "Imaging of Skull Base Cerebrospinal Fluid Leaks in Adults". *Radiology* 248 (3): 725–36.

20 Gordon, N. (2009). "Spontaneous intracranial hypotension". *Developmental Medicine & Child Neurology* 51 (12): 932–935

21 Mokri, B. (1999). "Spontaneous cerebrospinal fluid leaks: from intracranial hypotension to cerebrospinal fluid hypovolemia--evolution of a concept". Mayo Clinic proceedings. Mayo Clinic 74 (11): 1113–1123.

22 Schievink, W. I. (2008). "Spontaneous spinal cerebrospinal fluid leaks". *Cephalalgia : an international journal of headache* 28 (12): 1345–1356.

23 Leep Hunderfund, A. N.; Mokri, B. (2011). "Second-half-of-the-day headache as amanifestation of spontaneous CSF leak". Journal of Neurology 259 (2): 306–10.

24 Hofmann, E.; Behr, R.; Schwager, K. (2009). "Imaging of cerebrospinal fluid leaks".*Klinische Neuroradiologie* 19 (2): 111–121

25 Abuabara, A (2007). "Cerebrospinal fluid rhinorrhoea: diagnosis and management". *Medicina oral, patologia oral y cirugia bucal* 12 (5): E397–400.