

Original Article



Assessment of Mean American Knee Society Score for Complex Plateau Fractures with Ilizarov External Fixation

Fahad Hassan¹, Abdul Qadeer Khan Sadiq², Wazir Ahmed³, Nadeem Hassan⁴, Suresh Kumar⁵,
Najmuddin Fazlani⁶

¹Medical Officer, Primary and Secondary Health Care department, Punjab

²Medical officer, Primary and secondary health care department, KPK

³Assistant Professor, Bolan Medical College Quetta,

⁴Medical officer, Pakistan Institute of Medical Science, Islamabad

⁵Associate Professor of Anesthesiology, PIMS, SZABMU, Islamabad

⁶Senior Registrar, Department of orthopaedic surgery BMC, LUMHS/Jamshoro

Author's Contribution

^{1,4,6}Substantial contributions to the conception or design of the work; or the acquisition, Drafting the work revising it critically for important intellectual contests, ⁵Final approval of the version to be published, ^{2,3}Analysis, Literature review

Funding Source: None

Conflict of Interest: None

Received: Feb 03, 2023

Accepted: Aug 19, 2023

Address of Correspondent

Dr. Fahad Hassan
Medical Officer, Primary and Secondary Health Care department, Punjab
dr.fahadhassan@gmail.com

ABSTRACT

Objective: To determine clinical outcomes based on the AKSS (American Knee Society Score) in patients with complex tibial plateau fractures treated using Ilizarov external fixation.

Methodology: This descriptive case series study was conducted at the Department of Orthopaedics, Pakistan Institute of Medical Sciences (PIMS), Islamabad, from November 2020 to November 2021. The study included patients aged 20 to 55 of both genders with Schatzker type V or VI tibial plateau fractures who underwent Ilizarov external fixation and surgery within one week of the injury. Informed consent was obtained from all patients before undergoing Ilizarov external fixation. Pin tract infections were monitored weekly, and radiological assessments were performed monthly. The decision to remove the fixator was based on evidence of bone healing from two different angles, along with a successful stress test after removing the rods between the first two rings. After the fixator was removed, patients wore a removable brace for 3 to 5 weeks to protect their limbs during weight-bearing. Six weeks after external fixation, patients were assessed for pain levels, knee and ankle range of motion, limb alignment, and functional status according to the AKSS. Data were collected and analyzed using SPSS version 20.

Results: The mean age of the patients was 32.4±8.7 years. Out of all the patients, 66.5% were male, and 33.5% were female. The AKSS score averaged 82.5±11.2, the mean duration of surgery was 41.5±9.3, and the mean range of motion (ROM) was 22.1±4.8. Clinical outcomes were classified as excellent in 47 (27.2%) patients, good in 57 (32.9%), while 48 (27.8%) and 21 (12.1%) had fair and poor clinical outcomes, respectively.

Conclusion: The Ilizarov external fixation technique appears to be a reasonably effective method for treating complex tibial plateau fractures.

Keywords: Tibial Plateau Fractures, Ilizarov, External Fixation, AKSS (American Knee Society Score)

Cite this article as: Hassan F, Sadiq AQK, Ahmed W, Hassan N, Kumar S, Fazlani N. Assessment of Mean American Knee Society Score for Complex Plateau Fractures with Ilizarov External Fixation. Ann Pak Inst Med Sci. 2023; 19(3):245-250. doi.10.48036/apims.v19i3.893

Introduction

Complex plateau fractures of the knee pose significant challenges, often requiring intricate management strategies. They account for just 1% of all fractures and are

typically the result of high-energy mechanisms. These fractures can be associated with damage to nearby structures such as blood vessels, ligaments, nerves, and surrounding compartments.¹ The estimated annual occurrence rate for these fractures is 10.3 per 100,000

people, with an average age of 52.6 years for those experiencing tibial fractures.² The occurrence pattern of these fractures shows two distinct peaks: men under 50 years of age tend to experience such injuries through high-energy mechanisms, while women over 70 years of age are more prone to tibial plateau fractures resulting from falls. In general, men are at a higher risk of sustaining these severe fractures compared to women.^{3,4} Tibial plateau fractures can manifest as lateral, medial, or bicondylar injuries. Among these, lateral tibial plateau fractures are the most frequent and often result from a blow to the lateral aspect of the knee. In contrast, medial plateau injuries typically necessitate greater force and are usually associated with high-energy mechanisms, such as axial loading from falls from a height, impact in motor vehicle collisions, and other forms of direct trauma.⁴ When it comes to high-energy mechanisms like these, bicondylar fractures tend to be more prevalent compared to isolated medial plateau fractures. On the other hand, tibial plateau fractures resulting from low-energy mechanisms are more frequently seen in elderly individuals or other populations with osteoporotic conditions.^{4,5}

Plain radiographs should encompass anterior-posterior, lateral, and intercondylar notch perspectives. Nevertheless, identifying tibial plateau fractures on these images can be challenging, as they have a sensitivity rate of 85%.⁴ These injuries are linked to substantial morbidity and often necessitate surgical intervention. As a result, in cases where there is a strong suspicion of such fractures despite negative findings on plain radiographs, the use of CT or MRI is advisable. Schatzker Classification system is used for visualization of tibial plateau.⁶

Management of these fractures includes both operative and non-operative approaches. Non-operative management may involve long leg casts and traction mobilization. Operative treatment consists of open reduction with internal fixation (ORIF), which is recommended for tibial fractures displaying substantial articular misalignment, condylar widening, ligament instability, or "Schatzker IV to VI injuries".⁷ In cases where the injury is too fragmented for internal fixation, an external fixation approach with partial open or percutaneous fixation of the articular segment may be considered. In situations involving significant soft tissue damage or when the patient has sustained other critical injuries demanding immediate attention, the implementation of ORIF may be postponed, and temporary spanning external fixation may be employed as an interim measure.^{7,8}

The use of the Ilizarov external fixation method is an appealing treatment choice with several advantages. These advantages include achieving closed or minimally invasive fracture reduction with a reduced risk of wound complications, facilitating early joint motion, enabling functional loading and early weight-bearing, and the potential to enhance alignment and reduction while utilizing the fixator. Additionally, if a knee replacement becomes necessary in the future due to arthritis, it is technically simpler with this method as it doesn't require extensive incisions, poses fewer challenges with soft tissue coverage, and doesn't involve the introduction of substantial internal hardware.¹⁰

The incidence and severity of complications were greater with open reduction and internal fixation for complex tibial plateau fractures, according to a multi-center, prospective, randomized trial comparing internal fixation versus Ilizarov external fixation. On the other hand, Ilizarov external fixation leads to a shorter hospitalization period and a slightly faster return to normal function.^{9,10} Subramanyam et al. reported mean AKSS scores of 83.9 ± 7.1 SD with minimal internal fixation and 80.3 ± 10.55 with external fixation [10]. Al-Shahrani et al. reported that 33.3% of patients showed good clinical outcomes using AKSS, while 16% showed poor clinical outcomes after Ilizarov external fixation for complex tibial plateau fractures.¹¹

The area near the proximal tibia and the junction between the metaphysis and diaphysis is a crucial weight-bearing zone. An injury in this vicinity can either be limited to the tibia itself or be associated with substantial soft tissue damage.¹² While Ilizarov external fixation for managing tibial plateau fractures is internationally recognized as an effective treatment, local data on its effectiveness is limited. However, the present study aims to enhance our understanding of the best treatment options, with a focus on the local context.

Methodology

From November 2020 to November 2021, a one-year study period was allocated for this descriptive case series investigation, which took place at the Department of Orthopaedics, Pakistan Institute of Medical Sciences (PIMS), Islamabad, Pakistan. The study included patients aged 20-55 of both genders who had Schatzker type V or VI tibial plateau fractures. These patients were treated with Ilizarov external fixation and underwent surgery within one week of their injury. They were followed up for at least three months after the removal of the external fixator.

Patients with medical conditions or surgical interventions that could significantly impact knee function and confound the assessment of Ilizarov treatment outcomes, as well as patients with neurovascular injuries, a history of similar surgeries or fractures, severe cognitive impairment, communication barriers that hinder accurate AKSS reporting, or those unwilling or unable to participate in the AKSS assessment process were excluded.

The hospital's ethics committee granted ethical permission, and the qualified patients provided signed informed consent. Closed and open tibial plateau fractures of Schatzker type V or VI were selected using non-probability consecutive sampling. Upon admission, their distal neurovascular status was assessed, and initial wound cleaning and, when possible, wound closure were performed for open fractures. Antibiotics were administered according to the open fracture protocol. Patients received limb elevation, splinting, and measures to reduce swelling. X-rays were taken for all patients, and CT scans were conducted when deemed necessary for specific cases. Surgical stabilization was performed for all patients as soon as their skin condition improved and they were deemed suitable for anesthesia. All patients underwent surgery under spinal anesthesia. Indirect reduction was achieved using either calcaneal traction on a fracture table or a femoral distractor on a radiolucent table, with continuous radiological monitoring of the knee's desired degree of flexion. Open reduction was performed through minor incisions when necessary, and clamps were applied. In cases where condylar depression persisted, the joint line was raised by creating a metaphyseal opening and using cortico-cancellous bone graft obtained from the iliac crest on the same side of the body. In specific instances, 7 mm cannulated cancellous screws (CCS) were used to preserve the alignment of fracture fragments.

Following this, the Ilizarov apparatus was set up, with the initial ring positioned near the tibia's joint area, the second ring just under the fracture location, and the third ring in the area above the ankle joint. Tensioned olive wires were utilized to maintain the alignment of the fractured area, while non-olive wires were applied to stabilize the other segments. In a few cases, 5 mm Schanz screws were employed in the diaphyseal segments based on the surgeon's discretion. Patients with extensive fragmentation of the joint or ligament instability had their knees stabilized with a sole lower femoral ring for a duration of 16 weeks. Patients received weekly clinical follow-ups to monitor pin tract infections, while axial alignment and

radiological assessments were conducted every four weeks. The decision to remove the fixator was made after observing evidence of bone bridging from two different angles and conducting a successful stress test following the removal of rods between the initial two rings. After the fixator was removed, a removable brace was used to safeguard the limbs during weight-bearing for a period of 3 to 5 weeks, contingent on the results of the stress test.

Clinical progress was assessed using the American Knee Society Scores (AKSS) six weeks' post-treatment. The AKSS comprises three components: pain (with a maximum score of 50 points), knee stability (up to 25 points), and range of motion (with a maximum of 25 points). This results in a total score of 100 points, with deductions made for factors such as flexion contracture, extensor lag, and misalignment. The outcome, as per the AKSS, is categorized as excellent (score of 85 or higher), good (scores between 75 and 84), fair (scores ranging from 60 to 74), and poor (scores less than 60). Data was analyzed using SPSS version 26.

Results

A total of 173 patients were included to evaluate the clinical outcomes of complex tibial plateau fractures treated with Ilizarov external fixation. The mean age of the participants was 32.4±8.7 years. In terms of BMI, the mean value was 26.5 kg/m², with a standard deviation of 5.6 kg/m². The duration of surgery had a mean of 41.5 minutes, with a standard deviation of 9.3 minutes, indicating that surgery times also varied among the participants. (Table I)

Table I: Descriptive statistic of age, BMI and duration of surgery. (n=173)

Statistics	Age	BMI	Surgery duration
Mean	32.4 years	26.5 kg/m ²	41.5 minutes
Standard deviation	8.7 years	5.6 kg/m ²	9.3 minutes
Minimum	20 years	16 kg/m ²	30 minutes
Maximum	55 years	34 kg/m ²	120 minutes

Mean AKS score was 82.5± 11.2 and mean range of motion was 22.1±4.8 as shown in table II.

Table II: Descriptive statistics of AKS score and ROM. (n=173)

Statistics	AKS score	ROM
Mean	82.5	22.1
Standard deviation	11.2	4.8
Minimum	00	00
Maximum	100	25

Out of 173 patients, 115 (66.5%) were male while 58 (33.5%) were female. Pain was noted for 65 (37.6%)

patients. Knee stability was found in 120 (69.4%) patients as shown in figure 1.

Clinical outcomes were classified as excellent was noted in 47 (27.2%) patients, good for 57 (32.9%), while 48 (27.8%) and 21 (12.1%) had fair had poor clinical outcomes. (Figure 2)

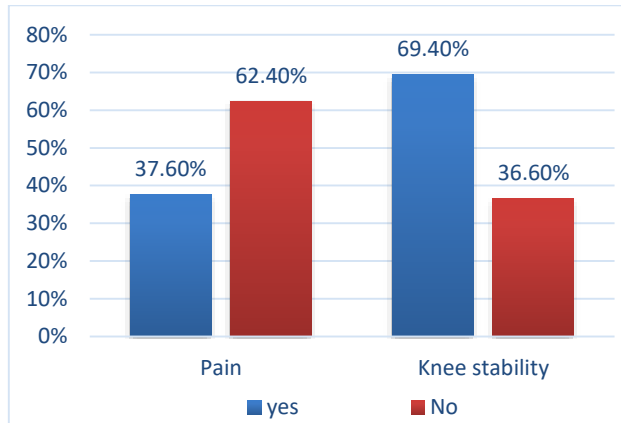


Figure 1. Pain occurrence and knee stability. (n=173)

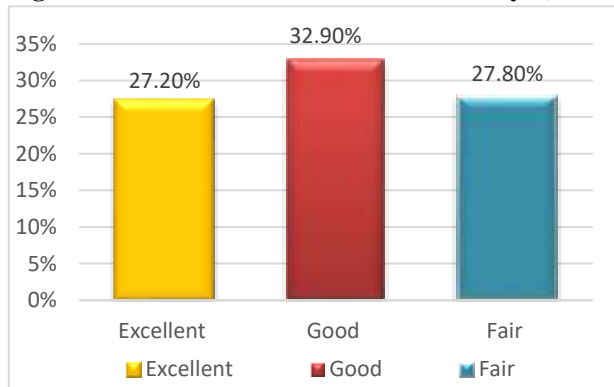


Figure 2. Clinical outcomes. (n=173)

In the evaluation of clinical outcomes for a total of 173 study participants based on patient age, gender, and BMI, four categories of clinical outcomes - Excellent, Good Fair and Poor were considered. The difference in outcomes between age groups was found to be statistically significant with a p-value of 0.002. However, there was no statistically significant difference in clinical outcomes based on gender and BMI, as indicated by p-values greater than 0.05. (Table II)

Discussion

Complex tibial plateau fractures pose a formidable surgical challenge.^{13,14} These difficulties arise from various factors, including the fracture pattern (such as articular depression, diaphyseal involvements and the condylar comminution), accompanying soft tissue and ligament injuries, concurrent neurovascular damage, and the potential for compartment syndrome.¹³ Some research indicates that a combination of a ring fixation system and minimal internal fixation leads to improved clinical results.¹⁴ Additionally, the use of an external fixator as the primary treatment for patients with complex tibial plateau fractures has been documented in the literature.¹⁵

Current has been done to evaluate clinical outcome based on AKSS for complex tibial plateau fractures with Ilizarov external fixation, with an average age of 32.4±8.7 years with male to female ratio approximately as 2:1. Our findings align with several other studies in terms of patient demographics. Comparatively, Catagni MA et al¹⁴ reported a mean age of 43 years, Shi D et al. noted an age of 33±9.6 years,¹⁶ and Thiagarajah S et al. reported an average age of 43 years.¹⁷

Additionally, Papadakis SA found the mean age to be 39.5, and Subramanyam KN et al. reported a mean age of 43.33 years.¹⁰ Furthermore, our study revealed a mean body mass index of 26.5±5.6 kg/m², an average American knee scoring score (AKSS) of 82.5±11.2, a mean surgical duration of 41.5±9.3 minutes, and an average range of motion (ROM) of 22.1±4.8. In our sample of 173 patients, there were 115 (66.5%) males and 58 (33.5%) females.

These gender proportions are consistent with the findings of Al Shahrani AA et al., who reported 75% males and 25% females. Another study noted 40 (67.8%) men and 19 (32.2%) women.¹² The study by Thiagarajah S et al¹⁷ found that 54 (67.5%) of their patients were male, while Subramanyam KN et al.¹⁰ reported 80% males and 20% females in their study. These comparisons illustrate the general consistency of our study's demographics with other relevant studies. The higher incidence of tibial plateau fractures among males can be partially attributed to the differences in participation in certain activities.

Table II: Clinical examination according to patient's age, gender and BMI. (n=173)

Variables	Clinical outcomes				P value
	Excellent	Good	Fair	Poor	
Age groups	18 – 40 years	36(20.8%)	27(15.6%)	19(11.0%)	0.002
	>40 years	11(6.4%)	30(17.3%)	29(16.8%)	
Gender	Males	35(20.2%)	40(23.1%)	26(15.0%)	0.175
	Females	12(6.9%)	17(9.8%)	22(12.7%)	
BMI	<25 kg/m ²	31(17.9%)	36(20.8%)	22(12.7%)	0.088
	≥25kg/m ²	16(9.2%)	21(12.1%)	26(15.0%)	

Outdoor activities, especially those that involve high-risk sports and recreational pursuits like motorcycle riding, and other physically demanding activities, are more frequently undertaken by males.

In the present study, pain was reported by 65 (37.6%) of the patients, while knee stability was noted in 120 (69.4%) of the cases. Regarding clinical outcomes, we observed that 47 (27.2%) patients achieved an excellent outcome, 57 (32.9%) were classified as good, 48 (27.8%) were considered fair, and 21 (12.1%) had poor outcomes. Comparatively, Catagni MA et al.¹⁴ found that clinical outcomes in their study were excellent among 50.85% of the cases, good outcomes observed in 45.76% of the study subjects, only one case showed fair outcomes and in case observed poor outcomes. Papadakis SA et al. reported good or excellent outcomes in 21 (46.67%) patients and poor or fair outcomes in 10 (22.22%) patients.¹⁷ In the study by Subramanyam KN et al.¹⁰ (53.33%) patients had excellent outcomes, 08 (26.67%) were classified as good, 05 (16.5%) had fair outcomes, and 01 (3.5%) had a poor outcome.¹⁰

Our findings were also supported by Kateros K et al.¹⁸ as patients with joint depression remaining at less than 3.5 mm had a 95% likelihood of achieving excellent AKSS knee scores and an 80% likelihood of attaining excellent AKSS function scores. Conversely, individuals with joint depression exceeding 4.5 mm demonstrated a 100% probability of receiving poor to fair scores in both AKSS knee and AKSS function evaluations. In the line of this series Ghimire A et al.¹⁹ also observed that the Ilizarov external fixation emerges as a secure, economically viable, and effective treatment approach for addressing complex tibial plateau fractures of Schatzker Types V and VI, ultimately yielding a favorable result. Our findings were also supported by few other studies.²⁰⁻²² These comparisons highlight the variations and similarities in clinical outcomes among the different studies, providing valuable insights into the effectiveness of the treatment method. Complex plateau fractures of the knee are challenging injuries that often require intricate management strategies. Among the various methods of treatment, Ilizarov external fixation has emerged as a valuable technique for stabilizing these fractures, promoting fracture healing, and preserving knee joint function. To assess the outcomes of such interventions, healthcare professionals often turn to the American Knee Society Score (AKSS), a comprehensive tool designed to evaluate the functional and clinical status of the knee joint.

Current study possesses several limitations as the study may be limited by the relatively small sample size of 173 patients, a larger sample could potentially provide more robust insights into clinical outcomes. Furthermore, the study's specific location may limit the generalizability of its findings. The results may not fully represent the varied populations, regions, and healthcare settings that exist. To enhance the external validity of the findings and broaden the representation of diverse patient populations, it would be beneficial to expand the research to multiple healthcare centers and regions. Additionally, the study predominantly focuses on Ilizarov external fixation as the treatment method for complex tibial plateau fractures. This singular focus restricts the ability to compare the effectiveness of this treatment against alternative approaches. Comparative analyses with other treatment methods would offer a more comprehensive perspective on the relative efficacy of various treatments. Looking forward, it is recommended that future research considers prospective study designs to mitigate biases and improve data accuracy. Additionally, incorporating patient-reported outcomes and quality of life assessments in future studies would provide a more holistic understanding of the treatment's impact on patients' lives, beyond clinical outcomes.

Conclusion

It is to be concluded that Ilizarov external fixation technique is somewhat effective method for the treatment of complex tibial plateau fractures. In the future, it is essential to carry out randomized studies with a significant number of participants, involving multiple research centers in Pakistan. This is necessary to validate the results obtained in the current study.

References

1. Mthethwa J, Chikate A. A review of the management of tibial plateau fractures, *Musculoskelet Surg*. 2018;102(2):119-127. <https://doi.org/10.1007/s12306-017-0514-8>
2. Elsoe R, Larsen P, Petruskevicius J, Kold S. Complex tibial fractures are associated with lower social classes and predict early exit from employment and worse patient-reported QOL: a prospective observational study of 46 complex tibial fractures treated with a ring fixator. *Strategies Trauma Limb Reconstr*. 2018;13(1):25-33. <https://doi.org/10.1007/s11751-017-0301-y>
3. Elsoe R, Larsen P, Nielsen NP, Swenne J, Rasmussen S, Ostgaard SE. Population-Based Epidemiology of Tibial Plateau Fractures. *Orthopedics*. 2015;38(9):e780-6. <https://doi.org/10.3928/01477447-20150902-55>

4. Malik S, Herron T, Mabrouk A, Rosenberg N. Tibial plateau fractures. InStatPearls [Internet] 2022 Sep 25.
5. Mustonen AO, Koivikko MP, Lindahl J, Koskinen SK. MRI of acute meniscal injury associated with tibial plateau fractures: prevalence, type, and location. *AJR Am J Roentgenol.* 2018;191(4):1002-9. <https://doi.org/10.2214/AJR.07.3811>
6. Timmers TK, van der Ven DJ, de Vries LS, van Olden GD. Functional outcome after tibial plateau fracture osteosynthesis: a mean follow-up of 6 years. *Knee.* 2014;21(6):1210-5. <https://doi.org/10.1016/j.knee.2014.09.011>
7. Ilyas M, Gupta A, Sharma S, Dev G. Multi-detector computed tomographic evaluation of tibial plateau fractures with review of Schatzker's classification of tibial plateau fractures. *Advances in Human Biology.* 2018;8(3):164. https://doi.org/10.4103/AIHB.AIHB_60_17
8. Ozkaya U., Parmaksizoglu A.S. Dual locked plating of unstable bicondylar tibial plateau fractures. *Injury.* 2015;46(2):S9-13. <https://doi.org/10.1016/j.injury.2015.05.025>
9. Ferreira N., Marais L.C. Bicondylar tibial plateau fractures treated with fine-wire circular external fixation. *Strat Trauma Limb Reconstr.* 2014;9(2):25-32. <https://doi.org/10.1007/s11751-014-0185-z>
10. Subramanyam KN, Tammanaiah M, Mundargi AV, Bhoskar RN, Reddy PS. Outcome of complex tibial plateau fractures with ilizarov external fixation with or without minimal internal fixation. *Chin J Traumatol.* 2019;22(3):166-71. <https://doi.org/10.1016/j.cjtee.2018.11.003>
11. Al Shahrani AA, Tedla SJ, Ahmad I. Effectiveness of ilizarov external frame fixation on functional outcome in aseptic tibial non-union cases at Abha, Kingdom of Saudi Arabia: an experimental study. *JTUMS.* 2016;10(2):216-21 <https://doi.org/10.1016/j.jtumed.2014.09.002>
11. Subramanyam KN, Tammanaiah M, Mundargi AV, Bhoskar RN, Reddy PS. Outcome of complex tibial plateau fractures with Ilizarov external fixation with or without minimal internal fixation. *Chinese Journal of Traumatology.* 2019 Jun 1;22(03):166-71. <https://doi.org/10.1016/j.cjtee.2018.11.003>
12. Chin TY, Bardana D, Bailey M, Williamson OD, Miller R, Edwards ER, Esser MP. Functional outcome of tibial plateau fractures treated with the fine-wire fixator. *Injury.* 2005;36(12):1467-75. <https://doi.org/10.1016/j.injury.2005.05.008>
13. El Barbary H., Abdel Ghani H., Misbah H. Complex tibial plateau fractures treated with Ilizarov external fixator with or without minimal internal fixation. *Int Orthop.* 2005;29:182-185 <https://doi.org/10.1007/s00264-005-0638-6>
14. Catagni MA, Ottavian G, Maggioni M. Treatment strategies for complex fractures of the tibial plateau with external circular fixation. *J Trauma.* 2007;63:1043-53 <https://doi.org/10.1097/TA.0b013e3181238d88>
15. Watson JT, Coufal C: Treatment of complex lateral plateau fractures using Ilizarov techniques. *Clin Orthop Relat Res.* 1998;353:97-106 <https://doi.org/10.1097/00003086-199808000-00012>
16. Shi D, Liu K, Zhang H, Wang X, Li G, Zheng L. Investigating the biomechanical function of the plate-type external fixator in the treatment of tibial fractures: a biomechanical study. *BMC Musculoskelet Disord.* 2020;21(1):1-9. <https://doi.org/10.1186/s12891-020-3144-5>
17. Thiagarajah S, Hancock GE, Mills EJ, McGregor-Riley JC, Royston SL, Dennison MG. Malreduction of tibial articular width in bicondylar tibial plateau fractures treated with circular external fixation is associated with post-traumatic osteoarthritis. *J Orthop.* 2019; 16(1):91-6. <https://doi.org/10.1016/j.jor.2018.12.016>
17. Papadakis SA, Pallis D, Ampadiotaki MM, Gourtzelidis G, Kateros K, Macheras G. Treatment of schatzker type II-VI tibial plateau fractures by means of syndesmotaxis using an ilizarov external fixator and postoperative CT evaluation. *Cureus.* 2021;13(1). <https://doi.org/10.7759/cureus.12680>
18. Kateros K, Galanakos SP, Kyriakopoulos G, Papadakis SA, Macheras GA. Complex tibial plateau fractures treated by hybrid external fixation system: A correlation of followup computed tomography derived quality of reduction with clinical results. *Indian J Orthop* 2018;52:161-9 https://doi.org/10.4103/ortho.IJOrtho_300_16
19. Ghimire A, Devkota P, Bhandari KK, Kharel Y, Pradhan S. Ilizarov Ring External Fixation for Complex Tibial Plateau Fractures. *Revista Brasileira de Ortopedia.* 2022 Sep 2;57:667-74. <https://doi.org/10.1055/s-0041-1739171>
20. Fayed MM, Elgebeily MA, Elkersh MA, Eisa MM. Ilizarov versus internal fixation in management of complex tibial plateau fracture. Which is better?. *QJM: An International Journal of Medicine.* 2020;113(Supplement_1):hcaa059-006. <https://doi.org/10.1093/qjmed/hcaa059.006>
21. DAR UF, IMTIAZ U. Ilizarov Hybrid External Fixation for Schatzker V and VI Tibial Plateau Fractures. *Age (years).*;30(30):33-.
22. dad Khan H, Khan Z, Ahmed T, Khan R, Khan K. Outcome of Schatzkar Type VI Tibial Plateau Fractures Treated with Ilizarov External Fixator. *Journal of Pakistan Orthopaedic Association.* 2018;30(4):143-7.