

Non Surgical Causes of Acute Abdomen in Children: Surgeons Standpoint for Exclusion

Muhammad Tahir Ghani¹, Ambreen Mobaraz², Huma Azam Malik³, Adil Rafiq⁴, Fareeha Ajmal⁵

¹Head of department Surgery/ Principal Medical Officer, Aero Hospital Hassan abdal,

²HOD / Child Specialist, Aero Hospital Hassan abdal

³Consultant Surgeon, Aero Hospital Hassan abdal, ⁴Principal Medical Officer, Aero Hospital Hassan abdal

⁵Medical officer Shifa Int. Hospital Islamabad

Author's Contribution

^{1,2}Substantial contributions to the conception or design of the work; or the acquisition, analysis, or interpretation of data for the work, manuscript writing.

^{3,4}Drafted the article or revised it critically for important intellectual content, Approved the version to be published

⁵Active participation in active methodology, literature search, data analysis

Funding Source: None

Conflict of Interest: None

Received: Dec 17, 2022

Accepted: May 24, 2023

Address of Correspondent

Dr. Muhammad Tahir Ghani
Head of department Surgery/
Principal Medical Officer Aero
Hospital Hassan abdal
doctortahir226@gmail.com

ABSTRACT

Objectives: The aim of this study is to find out the non-surgical causes of acute abdomen, their frequencies, and to make an algorithm to make a methodology for excluding surgical abdomen.

Methodology: This descriptive case series study was carried out in departments of pediatrics and surgery in Aero hospital from January 2021 to November 2022. One hundred children with acute abdomen who were referred for surgical opinion and found to have non-surgical abdomen were included in the study. Surgical causes were ruled out after serial examinations and investigations by consultant surgeons. All non-surgical causes, their frequencies of presentation were recorded and an algorithm was made. Descriptive data was analyzed using SPSS version 25.

Results: Gastroenteritis was found to be the most important cause of non-surgical acute abdomen and found in 23% (n=23) children followed by 18% (n=18) mesenteric lymphadenitis, nonspecific abdominal pain 12% (n=12), UTI 7% (n=7), worm infestation 7% (n=7), enteric ileitis 06% (n=6), Covid 05% (n=5), hepatitis 05%(n=5), constipation 04% (n=4), dengue 4% (n=4), ruptured ovarian follicle 3% (n=3), renal calculi 2% (n=2), Henoch schonlein purpura 2% (n=2) and gastritis 2% (n=2). An algorithm also made at the end of study to help treating surgeons to rule out surgical abdomen.

Conclusion: Gastroenteritis is the leading cause of acute non-surgical abdomen in children along with many other causes and these must be carefully ruled out by an algorithm to avoid unnecessary surgeries.

Key words: Non-surgical, acute abdomen, children.

Cite this article as: Ghani MT, Mobaraz A, Malik HA, Rafiq A, Ajmal F. Non-Surgical Causes of Acute Abdomen in Children: Surgeons Standpoint for Exclusion. *Ann Pak Inst Med Sci.* 2023; 19(2):63-68. doi. 10.48036/apims.v19i2.734

Introduction

Children get sick quickly¹ but they recover quickly if treated rightly and promptly. Acute abdomen is defined as acute abdominal pain of sudden and severe onset.² Acute abdomen in children is a serious condition that, if not treated correctly, have considerable morbidity and mortality.³ Acute abdomen in children is difficult to treat as history is either not available or is not accurate in younger children, and in most of the times physicians will only find a crying child.⁴ This makes situation very difficult, even for a shrewd and wise clinician. The anxiety of parents also contributes significantly to increase the difficulty of the whole situation.^{5,6} Diagnosis

of acute abdomen in children depends on history, examination, and investigations.^{4,6} Acute abdomen in children can be caused by a variety of surgical and non-surgical causes.³ Common surgical causes of acute abdomen in children include acute appendicitis, intussusception, intestinal obstruction, obstructed hernia, malrotations, torsion ovary and intestinal perforations.^{3,4,7}

There are many non-surgical or medical conditions like gastroenteritis, mesenteric lymphadenitis, and nonspecific abdominal pain with which children can present with acute abdomen.^{7,8} Sometimes in children, the differentiation of surgical from non-surgical abdomen becomes very difficult. Younger children do not give a proper history, and examination is also difficult as the

child is often seen crying. In a crying child abdominal examination is misleading, and whole abdomen is found tense with muscle cramping. This can make situation difficult, even for experienced surgeons. As the most important job for treating physician is to differentiate surgical from non-surgical acute abdomen to avoid negative laparotomies⁹, an algorithm or methodology must be adopted for excluding surgical abdomen.

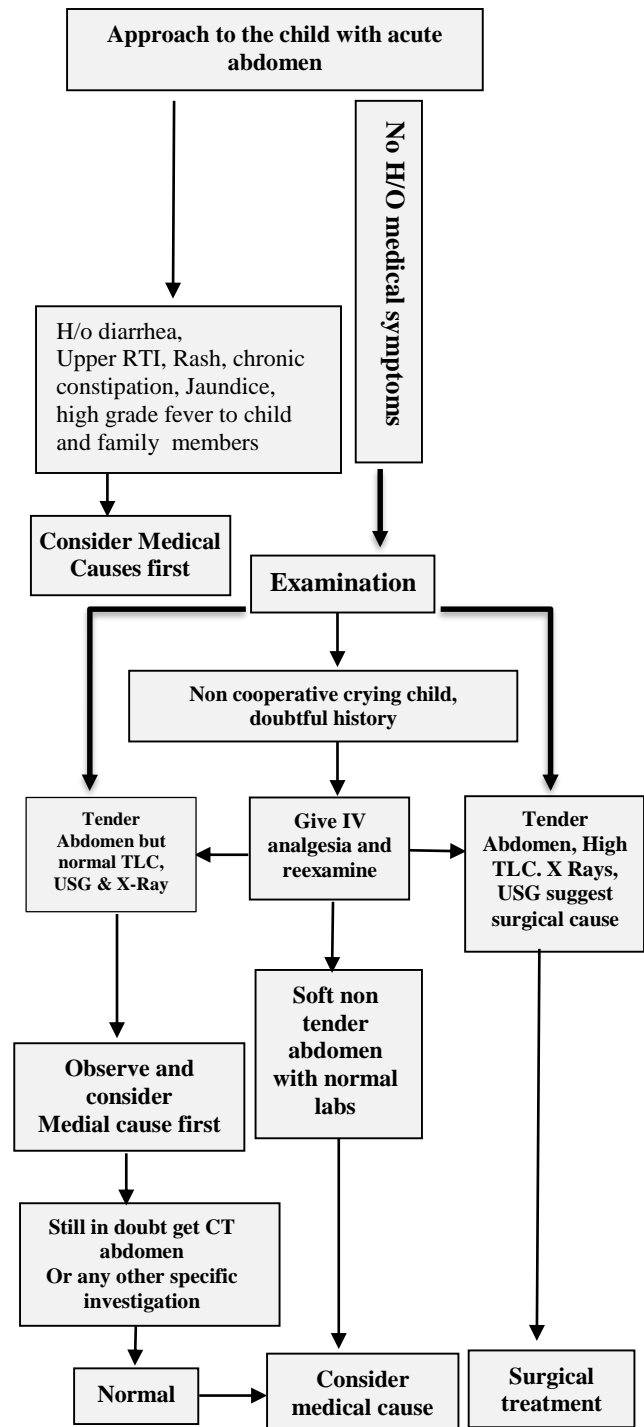
The majority of the previous studies highlight the surgical causes of acute abdomen^{10,11,12} and non-surgical causes of acute abdomen and their frequencies are not well studied. The aim of this study is to identify the common non-surgical causes of acute abdomen in children, their frequencies, and also to make an algorithm by which non-surgical abdomen can be better differentiated from surgical abdomen.

Methodology

This descriptive case series study was carried out in department of surgery and pediatrics AERO hospital wah cantt from January 2021 to November 2022. All children up to 12 years of age with acute abdomen that were referred from pediatric OPD, pediatric ward and emergency for surgical consultation, and no surgical pathology noted were included in study. The children who directly reported to surgical department with non-surgical acute abdomen were also included in study.

Children above 12 years of age, children with abdominal trauma, children with chronic pain abdomen and children with surgical causes of acute abdomen were excluded from the study. All surgical consultations were given by two consultant surgeons and surgical pathologies were excluded after history, examination and relevant investigations. The patients who were surgically excluded were referred back to pediatrics department with suspected diagnosis and final diagnosis recorded after consulting child specialist. Admitted patients were daily visited and progress recorded. Patients presenting to outpatient department were retained in emergency for first aid treatment and investigations and admitted to pediatric ward if needed. The patients who got better after initial management and confirmation of diagnosis were sent home with follow up advice. All discharged patients from ward or OPD had easy telephonic access to treating physicians and emergency department. Based on the observations and management of non-surgical acute abdomen in children in our study we have made an

algorithm (Figure 1) to help treating physicians in excluding surgical causes of pain.



Descriptive data was analyzed using SPSS version 25. Frequency table and algorithm were made by using Microsoft word 2013.

Results

One hundred consecutive children with acute abdomen were excluded by surgeons. Children sent for surgical consultations were 32% (n=32) from pediatric OPD, 25% (n=25) from pediatric ward and 22% (n=22) from emergency department. 21% (n=21) children directly reported to surgical OPD with acute abdominal pain. The age range of children was from 0-12 years. 05% (n=5) children were between 0-1 month of age, 19% (n=19) between 01 month - 01 year, 26% (n=26) between 01-05 years, 33 % (n=33) between 05-09 years and 17% (n=17) children were between 09-12 years of age (Figure 2). Among these children 23% (n=23) had gastroenteritis, 18% (n=18) mesenteric lymphadenitis, nonspecific abdominal pain 12% (n=12), UTI 7% (n=7), worms 07% (n=7), enteric ileitis in 06 (n=6), 05% Covid (n=5), hepatitis 05%(n=5), constipation 04% (n=4), dengue 04% (n=4) , ruptured ovarian follicle in 03% (n=3), renal calculi in 2% (n=2), Henoch schonlein purpura 2% (n=2), and gastritis was found in 2% (n=2) patients (Table I). 91 % (n=91) children were excluded on the basis of history, examination, routine blood tests (CP, CRP, URINE RE, LFTS, AMYLASE) Ultrasound abdomen and X-rays. CT scan abdomen with contrast was needed additionally in 09% (n=9) cases with doubtful diagnosis.

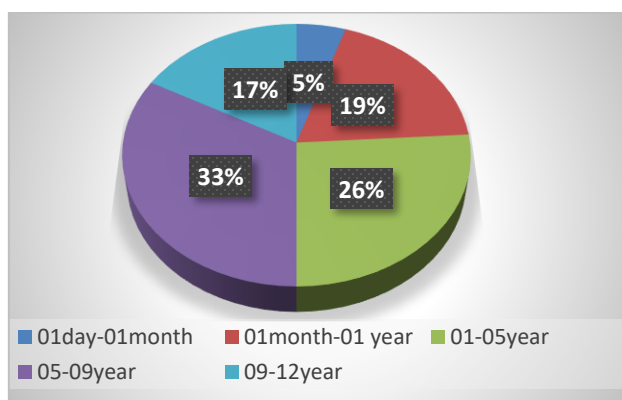


Figure 2. Age distribution of patients

Discussion

Acute abdomen in children is a diagnostic challenge.^{4,6} There are many surgical and nonsurgical causes of acute abdomen in children.^{3,4,7,8} Acute abdomen is considered a surgical emergency and dealt with by surgeons until proven otherwise or at least needs surgical exclusion.⁶ When the surgical cause is obvious, the management becomes straight forward but it is more difficult when there is no obvious surgical cause and the diagnosis is doubtful. Good coordination between paediatricians and

Table I: Diagnosis with frequencies and main diagnostic features.

Diseases	Frequencies	Main diagnostic features
Gastroenteritis	23%	h/o diarrhea, no guarding, normal ultrasound
Mesenteric lymphadenitis	18%	h/o upper RTI, ultrasound is diagnostic
Non specific abdominal pain	12%	h/o similar episodes in past , diagnosis of exclusion, no guarding
UTI	7%	Symptoms of UTI, abnormal urine RE, no guarding
Worm infestation	7%	h/o worms in stools, normal TLC and ultrasound, non tender
Enteric ileitis	6%	High grade fever, normal USG, positive cultures, leukopenia
Covid	5%	h/o Covid in family, no guarding, positive Covid test, USG NAD
Hepatitis	5%	Jaundice , deranged LFTS, USG diagnostic
Constipation	4%	h/o chronic constipation, normal USG, PR impacted stool
Dengue	4%	Epidemic phase, h/o fever in family, no gaurd , positive NS1,USG NAD
Ruptured ovarian follicle	3%	h/o menarche, no guard, normal TLC, USG or CT is diagnostic
Renal calculi	2%	Urine RE and USG is diagnostic
Henoch schonlein purpura	2%	Classic triad, no guard, USG normal
Gastritis	2%	Epigastric pain, normal blood tests, normal USG, positive H pylori

surgeons is essential for better management and outcome.^{3,6}

History of diarrhea, upper respiratory infection, cough, rash, jaundice, history of high grade fever since few days in the child and other family members with acute abdomen should lead the treating physician to look for non-surgical causes of acute abdomen first as highlighted by study conducted by Hijaz M et al.^{3,8} Coming across a crying child with an acute abdomen in an emergency poses a huge diagnostic challenge.¹⁴ On examination the whole abdomen looks guard and tender. Parenteral analgesia in minor doses according to body weight is a good regime to make child pain free and comfortable so he may let physician examine and make the correct diagnosis.¹⁵ In a study conducted by Poonai et al.¹⁵, the efficacy of low-dose narcotic analgesia in children with

acute abdomen was emphasized. Inspired by this approach, we employed the same regimen in our study and observed its significant utility Grundmann RT¹⁶ et al also found that approximately 50% physicians and pediatric surgeons give analgesia to children in emergency room before making diagnosis. If the abdomen is soft and non tender after analgesia non-surgical causes should be considered first. If the abdomen is tender with normal TLC, ultrasound abdomen and X rays, non-surgical causes should be considered first. Abdominal ultrasonography is an important, readily available and cheap diagnostic facility with high diagnostic yield in acute abdomen in children.^{17,18} In a study conducted by Scammel S et al¹⁸ Ultrasonography was found to have a sensitivity of 83.3%, a specificity of 97.4%, a positive predictive value of 92.1% and a negative predictive value of 94.0% in children with acute abdomen. A normal ultrasound abdomen when combined with a normal TLC count essentially rules out majority of causes of acute surgical abdomen. Many acute abdominal conditions in children need CT scan abdomen for diagnoses. However, the use of CT scan should be reserved for cases in which the diagnosis is not certain after routine blood tests, abdominal ultrasonography and x-rays.^{19,20} We did CT scan in only 9% (n=9) of cases with a doubtful diagnosis. In a study conducted by Coca RD²⁰ CT scan was carried out for few abdominal conditions that were not diagnosed on ultrasonography.

Gastroenteritis represents the predominant non-surgical etiology of acute abdomen in children across all age groups, as supported by multiple studies.^{3, 7, 8} Our study similarly identified acute gastroenteritis as the primary causative factor in 23% (n=23) of cases, aligning with the findings of Benergee et al.⁷ who reported it as the second most prevalent non-surgical cause of acute abdomen in children. Guarding and typical surgical tenderness is missing especially after giving analgesics and relaxants. Mesenteric lymphadenitis associated with upper respiratory infection is also common cause of acute nonsurgical abdomen.²¹ 18% (n=18) patients presented with mesenteric lymphadenitis in our study which is high as compared to the study conducted by Ozdamar MY²¹ in which 4.5% children with acute abdomen were diagnosed as having mesenteric lymphadenitis.

Nonspecific abdominal pain is common among children.²² Many proposed etiologies are labelled as the cause of acute abdomen in such cases.^{22,23} In our study we found 12% (n=12) of cases as having nonspecific abdominal pain. 7% patients (n=7) presented with

symptoms of UTI with severe abdominal pain. Abdominal pain may be a subjective feeling due to distress in these cases. Children with worm infestation can present with acute abdomen²⁴ and in our study we found 07% (n=7) cases of acute abdomen caused by worm infestation. A study conducted by Unal et al²⁴ also shows similar results and identifies many types of worms responsible for acute abdominal pain in children.

Enteric fever is endemic in our society, and children can present with acute abdomen, high grade fever, diarrhea or vomiting.²⁵ We found 06% (n=6) children with acute abdomen to have enteric ileitis. In a study conducted by Behera JR it was concluded that 21.43% cases of enteric fever in children present with acute abdominal pain. Acute viral infections like COVID and dengue fever can present as acute abdomen in children.^{13,26} In our study we found n=05 (5%) cases of Covid abdomen and 04 cases of dengue fever. Rico EC et al¹³ in his study found 19 Covid cases in children presenting acutely with pain abdomen. Covid PCR and dengue NS1 was positive in both patients respectively and managed conservatively.

Acute viral hepatitis can cause reactionary fluid intraperitoneally and thick walled gall bladder leading to acute abdominal pain. In study conducted by Chen YH et al²⁷ 42% children with hepatitis presented with acute abdominal pain. We found 05% (n=5) cases of viral hepatitis presenting with acute abdomen in our study. Constipation in children can present as an acute abdomen.²⁸ In a study conducted by Benergee R et al⁷ constipation was found to be highest cause of non surgical acute abdomen in children. We found 04% (n=4) cases of acute abdominal pain in children due to severe constipation.

Young girls after menarche presenting with acute lower abdominal pain with normal TLC should be screened for ruptured ovarian follicle¹⁴ or a tiny cyst. In our study, we found 3% (n=3) cases of ruptured ovarian follicle and severe pain. Ultrasound may not detect very small amount of fluid in pelvis and CT abdomen may be needed to confirm diagnosis. Age, female gender, post menarche, normal TLC should rise suspicion and children should be managed conservatively first before rushing for surgery.

Henoch schonlein purpura is an autoimmune disorder and children can present with acute abdomen.²⁹ In our study 02% (n=2) children presented with classic triad of purpura, pain abdomen and arthralgia. Two patients in

our study presented with acute gastritis. Symptoms were severe upper abdominal pain with nausea and vomiting. Routine blood tests, X rays and ultrasound were normal. Stress, drugs and *Helicobacter pylori* infection are proposed etiologies for gastritis and gastric ulcers in children.³⁰

Conclusion

Gastroenteritis is the leading cause of acute non-surgical abdomen in children, followed by mesenteric lymphadenitis, nonspecific abdominal pain, and many other. These must be carefully ruled out to avoid unnecessary surgeries in children.

References

- Ostergaard LR, Bjertrup PJ, Samuelsen H. "Children get sick all the time": A qualitative study of socio-cultural and health system factors contributing to recurrent child illnesses in rural Burkina Faso. *BMC Public Health*. 2016; 16(10):384-7. <https://doi.org/10.1186/s12889-016-3067-0>
- Xu X, Ye J. Clinical Value of Abdominal Ultrasonography in the Diagnosis of Acute Abdomen in Children. *Contrast Media Mol Imaging*. 2022; 23(6): 2681543. doi: 10.1155/2022/2681543. <https://doi.org/10.1155/2022/2681543>
- Hijaz NM, Friesen CA. Managing acute abdominal pain in pediatric patients: current perspectives. *Pediatric Health Med Ther*. 2017; Jun(8): 83-91. doi: 10.2147/PHMT.S120156. <https://doi.org/10.2147/PHMT.S120156>
- Raymond M, Marsicovetere P, DeShaney K. Diagnosing and managing acute abdominal pain in children. *JAAPA*. 2022; 35(1): 16-20.. <https://doi.org/10.1097/01.JAA.0000803624.08871.5f>
- Van TMA, Chitkara DK, Palsson OS, Levy RL, Whitehead WE. Parental worries and beliefs about abdominal pain. *J Pediatr Gastroenterol Nutr*. 2009; 48(3): 311-7. <https://doi.org/10.1097/MPG.0b013e31817c03ae>
- Nakayama DK. Examination of the Acute Abdomen in Children. *J Surg Educ*. 2016 73(3): 548-52. <https://doi.org/10.1016/j.jsurg.2016.01.007>
- Benergee R, Prasad A, Gupta S. clinical spectrum of acute abdomen in children admitted to pediatric emergency department: A prospective study. *Current medical research and practice*. 2019; 9(2): 49-52. <https://doi.org/10.1016/j.cmrp.2019.02.002>
- Reust CE, Williams A. Acute Abdominal Pain in Children. *Am Fam Physician*. 2016; 93(10): 830-6.
- Kanglie MMNP et al. The incidence of negative intraoperative findings after unsuccessful hydrostatic reduction of ileocolic intussusception in children: A retrospective analysis. *J Pediatr Surg*. 2019; 54(3): 500-6. <https://doi.org/10.1016/j.jpedsurg.2018.05.006>
- Syrett PJ, Heaton PA, Jenner L, Paul SP. Acute abdominal surgical presentations in children. *Br J Nurs*. 2021; 30(13): 780-6. <https://doi.org/10.12968/bjon.2021.30.13.780>
- Serban D, Tanasescu C. Acute surgical abdomen during the COVID-19 pandemic: Clinical and therapeutic challenges. *Exp Ther Med*. 2021; 21(5): 519. <https://doi.org/10.3892/etm.2021.9950>
- Tarca E, Trandafirescu MF, Cojocaru E, Mihaila D, Savu B. Mesenteric panniculitis, a rare cause of acute surgical abdomen in children. Case report and literature review. *Rom J Morphol Embryol*. 2017; 58(4):1597-04.
- Rico EC, Souto RH, Espinosa GR, Espinoza VML, Alonso CJL. Acute abdomen in COVID-19 disease: the pediatric surgeon's standpoint. *Cir Pediatr*. 2021; 34(1) :3-8. English, Spanish.
- Zhou H, Chen YC, Zhang JZ. Abdominal pain among children re-evaluation of a diagnostic algorithm. *World J Gastroenterol*. 2002; 8(5):947-51. <https://doi.org/10.3748/wjg.v8.i5.947>
- Poonai N, Zhu R. Analgesia for Children in Acute Pain in the Post-codeine Era. *Curr Pediatr Rev*. 2018; 14(1): 34-40. <https://doi.org/10.2174/1573396313666170829115631>
- Grundmann RT, Petersen M, Lippert H, Meyer F. The acute surgical abdomen epidemiology, diagnosis and general principles of management. *Z Gastroenterol*. 2010;48(6):696-06. <https://doi.org/10.1055/s-0029-1245303>
- Wunsch R, Wunsch C. Bildgebung b. Imaging of acute abdomen in childhood and adolescence. *Radiologe*. 2014; 54(9): 923-34. <https://doi.org/10.1007/s00117-014-2709-4>
- Scammell S, Lansdale N, Sprigg A, Campbell D, Marven S. Ultrasonography aids decision-making in children with abdominal pain. *Ann R Coll Surg Engl*. 2011; 93(5): 405-9. <https://doi.org/10.1308/rcsann.2011.93.5.405>
- Bax T, Macha M, Mayberry J. The utility of CT scan for the diagnostic evaluation of acute abdominal pain. *Am J Surg*. 2019;217(5):959-66. <https://doi.org/10.1016/j.amjsurg.2019.02.003>
- Coca RD, Liebana d, Rojas C, Aguirre PE. Abdominal emergencies in pediatrics. *Radiologia*. 2016;58 (2): 80-91. <https://doi.org/10.1016/j.rx.2016.02.003>
- Ozdamar MY, Karavaş E. Acute mesenteric lymphadenitis in children: findings related to differential diagnosis and hospitalization. *Arch Med Sci*. 2018; 16(2): 313-20. <https://doi.org/10.5114/aoms.2018.79430>
- Prada AM et al. Appendicitis or non-specific abdominal pain in pre-school children: When to request abdominal ultrasound. *J Paediatr Child Health*. 2020;56(3): 367-71. <https://doi.org/10.1111/jpc.14617>
- Thornton GC, Goldacre MJ, Goldacre R, Howarth LJ. Diagnostic outcomes following childhood non-specific abdominal pain: a record-linkage study. *Arch Dis Child*. 2016;101(4):305-9. <https://doi.org/10.1136/archdischild-2015-308198>

24. Unal et al. Parasitic diseases as a cause of acute abdominal pain: imaging findings. *Insights into Imaging*. 2020;11:86
<https://doi.org/10.1186/s13244-020-00892-5>
25. Behera JR, Rup AR, Dash AK, Sahu SK, Gaurav A, Gupta A. Clinical and Laboratory Profile of Enteric Fever in Children from a Tertiary Care Centre in Odisha, Eastern India. *Cureus*. 2021; 13(1): 12826.
<https://doi.org/10.7759/cureus.12826>
26. Al Araiimi H, AlJabri A, Mehmoud A, AlAbri S. Dengue Haemorrhagic Fever presenting as Acute Abdomen. *Sultan Qaboos Univ Med J*. 2011; 11(2): 265-8.
27. Chen YH et al. Diagnosis, treatment, and prevention of severe acute hepatitis of unknown etiology in children. *World J Pediatr*. 2022; 18(8):538-44.
<https://doi.org/10.1007/s12519-022-00581-x>
28. Loening BV, Swidsinski A. Constipation as cause of acute abdominal pain in children. *J Pediatr*. 2007;151(6): 666-9.
<https://doi.org/10.1016/j.jpeds.2007.05.006>
29. Leung AKC, Barankin B, Leong KF. Henoch-Schönlein Purpura in Children: An Updated Review. *Curr Pediatr Rev*. 2020; 16(4): 265-76.
<https://doi.org/10.2174/1573396316666200508104708>
30. Gottrand F. Abdominal pain and gastritis in children. *Rev Prat*. 2011; 61(5): 639-42.