

# Assessment of Clinicopathological Status and Outcome of Children with Tuberculous Meningitis at a Tertiary Care Hospital

Maqbool Hussain<sup>1</sup>, Sonaina Maqbool<sup>2</sup>, Maryam Masud<sup>3</sup>, Mishal Maqbool<sup>4</sup>, Abrar Ul Haq Satti<sup>5</sup>, Raza Hussain Shah<sup>6</sup>, Ravale Tashfeen<sup>7</sup>, Saleem Abbasi<sup>8</sup>

<sup>1</sup>Professor & Head of Pediatrics, Children Hospital, PIMS, <sup>2</sup>Ex House officer, SOD, Islamabad

<sup>3</sup>Ex House officer, PIMS, <sup>4</sup>Postgraduate Trainee, MCH, PIMS

<sup>5</sup>Senior Registrar, Department of Pediatrics, Rawal Institute of Health Sciences, Islamabad

<sup>6</sup>Ex-Postgraduate Student, Children Hospital, PIMS, Islamabad, <sup>7</sup>Shifa International Hospital, Islamabad

<sup>8</sup>Epidemiologist/Data Analyst, PMTI, Pakistan Institute of Medical Sciences, Islamabad

## Author's Contribution

<sup>1</sup>Supervised and Final approval of the version to be published

<sup>2-4</sup>Substantial contributions to the conception or design of the work, the acquisition,<sup>5,6</sup>Drafting the work or revising it critically for important intellectual content, <sup>7,8</sup>analysis, or interpretation of data for the work,

Funding Source: None

Conflict of Interest: None

Received: Dec 17, 2021

Accepted: July 21, 2022

## Address of Correspondent

Prof. Maqbool Hussain  
Professor & Head of Pediatrics,  
Children Hospital, PIMS  
drmaqboolhussain@gmail.com

## ABSTRACT

**Objective:** The aim of this study is to report the clinic-pathological profile of children with TBM and their treatment outcome.

**Methodology:** A retrospective observational study was conducted in the Pediatrics Department over 6 months period. Medical records of children admitted with TBM from November 2017 to May 2018 were reviewed for data collection. Data regarding clinical presentation, laboratory investigations were recorded. Patients were treated with a standard ATT regimen, and their outcome was noted. The study was approved by hospital ethics committee. Data was entered in SPSS for statistical analysis.

**Results:** Females were predominant 39 (55.7%) and age ranged from 4 months to 13 years in this study. Only 28 (42.0%) children were fully vaccinated and had BCG scar presence. Most TBM cases were of stage II 24 (42.8%) or stage III 29 (42.8%). The frequent symptoms were fever 61 (87.1%), rigidity/irritability 35 (50.0%), and seizures 26 (37.1%). WBCs count in CSF was found below 500 in 64 (91.4%) children. There were 55 (78.5%) children with lymphocytosis and 14 (20.0%) with polymorph nuclear cells. A CT scan was suggestive of TBM in 51 (72.8%) children. Only 21 (30.0%) cases had a complete recovery whereas 17 (24.2%) recovered with sequelae and 10 (14.2%) deaths were noted.

**Conclusion:** TBM presents with a poor clinical and pathological state in the advanced stage of the disease, and the therapy outcome is also non-satisfactory with high mortality and sequelae posing constant challenges.

**Keywords;** Tuberculous meningitis, clinical presentation, pathological findings, therapy outcome.

Cite this article as: Hussain M, Maqbool S, Masud M, Maqbool M, Satti AUH, Shah RH, Tashfeen R, Abbasi S. Assessment of Clinicopathological Status and Outcome of Children with Tuberculous Meningitis at a Tertiary Care Hospital. *Ann Pak Inst Med Sci.* 2022; 18(3):228-233. doi. 10.48036/apims.v18i3.722

## Introduction

Tuberculous Meningitis (TBM) in pediatric population is quite challenging. The complications associated with TBM are seizures, developmental delay, cranial nerve palsy, and deranged IQ level. Despite the effective National TB Control Program, data regarding TBM is scarce in Pakistan.

Tuberculosis (TB) is an infectious disease, that has shown significant morbidity and mortality, especially in

children.<sup>1</sup> Being a developing nation, Pakistan is included in the list of 30 high burden countries for TB and multidrug-resistant MDR-TB by the World Health Organization (WHO). Around 5.7 million people suffer from TB in Pakistan, with 260000 new cases occurring every year.<sup>2</sup> In the world's underdeveloped regions, the incidence of tuberculosis ranges from 110 to 165 cases per 100,000 people, with tuberculous meningitis accounting for up to 10% of these cases.<sup>3</sup>

Childhood TB is classified into two forms: i.e. Pulmonary Tuberculosis (PTB) and extrapulmonary tuberculosis (EPTB). EPTB usually presents as lymphadenopathy, pleural effusion, pericardial disease, ascites, joint and bone diseases, and meningitis.<sup>4</sup> Out of all, tuberculous involvement of the central nervous system (CNS) is not only common but also has a poor prognostic outcome in children. The neurological complications associated with TBM are seizures, developmental delay, cranial nerve palsy, blindness, deafness, impaired motor function, and a deranged IQ level.<sup>5</sup>

Even today, due to the diverse clinical signs and symptoms, diagnosing every case of tuberculous meningitis (TBM) in the pediatric population is quite challenging for pediatricians.<sup>6</sup> Despite the effective National TB Control Program, data regarding pediatric TBM is scarce in Pakistan. Children affected by TBM are at risk of developing various complications, resulting in lifelong disability.<sup>7</sup> To prevent this phenomenon and ensure a better outcome, early diagnosis and prompt treatment are essential. We designed this study to assess the clinical, and laboratory findings of children with TBM and also evaluate their outcome in response to treatment.

## Methodology

This study was conducted at the Children's Hospital, Pakistan Institute of Medical Sciences (PIMS), where data was collected from November 2017 to May 2018, over a period of 6 months. The study was a retrospective observational trial based on medical records of 70 children diagnosed with TBM who were admitted to the Children's Hospital from January 2016 to December 2017. CNS TB was confirmed in these patients by either microbiological laboratory or clinical criteria. The microbiologic and laboratory case definitions included; i) isolation of *Mycobacterium tuberculosis* (MTB) from cerebrospinal fluid (CSF), ii) cranial CT/MRI consistent with CNS TB, and iii) CSF findings consistent with TBM plus abnormal neurological symptoms and signs.

Clinical criteria for confirmation of TBM were defined by abnormal neurological signs or symptoms and more than two of the elements such as the discovery of the adult source of contagious TB and/or presence of positive Tuberculin skin test (TST). To look for complications of disease and response to therapy, we contacted the parents and followed them up in the TB clinic.

The stages of TBM were identified by the MRC staging system where stage 1 includes the prodromal phase with no neurological symptoms, stage 2 includes the signs of meningeal irritation with slight or no clouding of sensorium and minor or no neurological deficit. Whereas, stage 3 was labeled when there is a severe clouding of sensorium, convulsions, focal neurological deficit, or involuntary movements.

At our hospital, both arms of children were examined for BCG scar, and those patients with immunization recorded on cards but absent BCG scars were considered partially immunized. Malnourishment was classified according to WHO charts with the help of weight for age criteria.

Apart from detailed history and examination, a set of laboratory investigations was done in patients with TBM such as tuberculin test, CSF for biochemistry, microscopy and culture, gastric aspirate for gene expert. All cases underwent certain radiology investigations like chest X-ray, CT-scan Brain, and/or MRI Brain.

The children were labelled as category 1 cases in the TB clinic for cases receiving first antitubercular treatment (ATT). Whereas category 2, who had already completed ATT for either pulmonary or extra-pulmonary TB and later had a relapse.

Those patients diagnosed with TBM, are treated with a standard ATT regimen. It includes daily doses of isoniazid (10-15mg/kg), Rifampicin (15-20mg/kg), Ethambutol (20mg/kg), Pyrazinamide (20-35mg/kg) for first 02 months of treatment. Rifampicin and isoniazid are then continued for the next 10 months. These drugs were given either orally or through a nasogastric tube. A glucocorticoid (Dexamethasone at 0.3-0.5mg/kg per day) is also given for 01 months of treatment and then taper off over 7-14 days. These drugs were provided by the National TB Control Programme (NTP) of Pakistan. The preparation was FDC with combinations of isoniazid, rifampicin, ethambutol, and pyrazinamide.

The hospital's record room was used to collect data. Medical files were reviewed, and parameters like age, gender, weight, patient dwelling, socioeconomic status, history of contact, immunization, clinical presentation at admission along with their duration, stage of patient, and radiological and microbiological testing were entered on an especially designed questionnaire. Data was entered and analyzed in SPSS version 22.0. Using descriptive statistics, categorical variables were measured as frequencies and percentages.

## Results

Out of 70 patients, females were predominant in 39 (55.7%) while the remaining 31 (44.3%) were males. The female to male ratio was 1.2:1. Age ranged from 4 months to 13 years, with the majority of the cases above one year of age. Urban and rural distribution was equal (50.0%) in the study, while more than two-thirds of cases belonged to very poor to poor SES i.e., 20 (28.5%) with up to Rs. 10000/month and 28 (40.0%) patients having an income of Rs. 10000 to 25000/month. Only 22 (31.5%) belonged to lower-middle to middle-income strata with a monthly income of more than Rs. 25000/month. Approximately two-thirds of the cases (60.0%) were malnourished. Only 28 (42.0%) children were fully vaccinated and also had the presence of BCG scar. (Table I)

	No of cases	Age %
<b>Age (months)</b>		
Up to 12	10	14.2%
13 to 60	30	42.8%
61 to 180	30	42.8%
<b>Gender</b>		
Male	31	44.2%
Female	39	55.8%
<b>Residence</b>		
Urban	35	50.0%
Rural	35	50.0%
<b>Socioeconomic status</b>		
Up to 10000	20	28.5%
10001 to 25000	28	40.0%
Above 25000	22	31.5%
<b>Nutritional status</b>		
Malnourished	42	60.0%
Well-nourished	28	40.0%
<b>Vaccination status</b>		
Complete done	28	40.0%
Partial	11	15.8%
Not done	31	44.2%
<b>BCG scar</b>		
Present	28	40.0%
Absent	42	60.0%

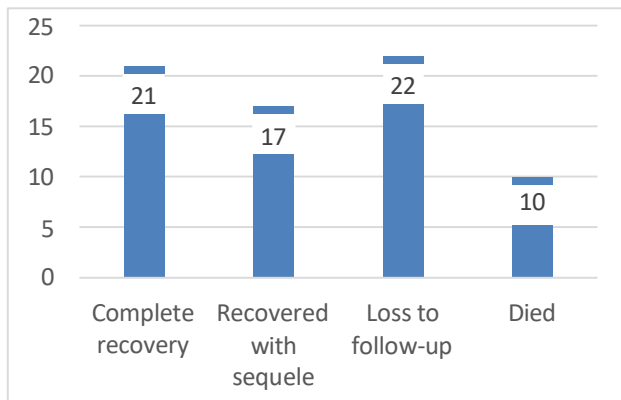
Most of the TBM cases in the study were stage II 24 (42.8%) or stage III 29 (42.8%) patients. The frequent symptoms were fever 61 (87.1%) followed by rigidity/irritability 35 (50.0%), seizures 26 (37.1%), headache 23 (32.8%) and vomiting 21 (30.0%). Duration of these symptoms was between 1 to 3 weeks in 24 (34.2%) children and more than 3 weeks in 31 (44.2%) cases. When different diagnostic tests were run, routine CSF was found suggestive of TBM in 64 (91.4%) cases. WBCs count in CSF was found below 500 in 64 (91.4%)

children. Protein levels in CSF were below 100 in 29 (42.8%) and between 100 to 200 in 21 (30.0%) cases. There were 55 (78.5%) children with lymphocytosis and 14 (20.0%) with polymorph nuclear cells. The glucose level was below 10 mg/dl in 8 (11.4%) cases whereas 32 (45.6%) patients had it between 40 to 80 mg/dl. CT scan was suggestive of TBM in 51 (72.8%) children, whereas MRI was found suggestive in 16 (22.8%) in whom it was conducted. On the gene expert test, there were 4 (5.7%) positive cases in this study. (Table II)

**Table II: Clinical and laboratory findings in the study (n=70)**

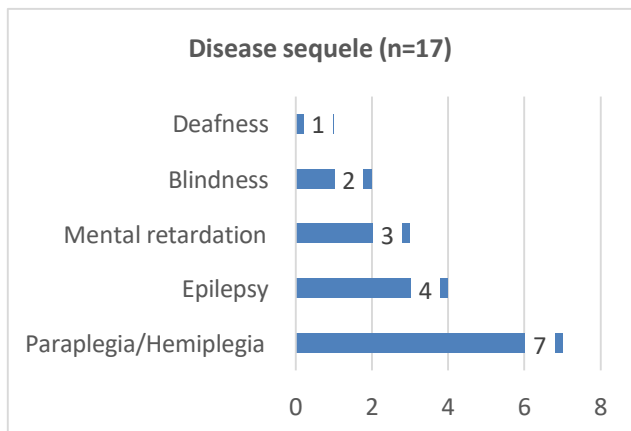
	No of cases	Age %
<b>Stage of TBM (n=68)</b>		
I	15	14.2%
II	24	42.8%
III	29	42.8%
<b>Symptoms (n=68)</b>		
Fever	61	87.1%
Vomiting	21	30.0%
Rigidity	35	50.0%
Seizures	26	37.1%
Headache	23	32.8%
Loss of appetite	12	17.1%
Weight loss	6	8.5%
Paresis	19	27.1%
<b>Duration of symptoms (n=68)</b>		
Up to 1 week	13	18.5%
1 to 3 weeks	24	34.2%
More than 3 weeks	31	44.2%
<b>Gastric lavage</b>	12	17.1%
<b>AFB smear in gastric lavage</b>	6	8.5%
<b>CSF R/E (n=69)</b>		
Suggestive	64	91.4%
Non-suggestive	5	7.1%
<b>WBC count (n=69)</b>		
< 500	64	91.4%
> 500	5	7.1%
<b>Predominance (n=69)</b>		
Lymphocytosis	55	78.5%
Polymorphonuclear cells	14	20.0%
<b>Protein (n=69)</b>		
< 100	29	41.4%
100 to 200	21	30.0%
> 200	19	27.1%
<b>Glucose (mg/dl) (n=69)</b>		
< 10	8	11.4%
10 to 40	29	41.4%
40 to 80	32	45.6%
<b>CT scan (n=53)</b>		
Suggestive	51	72.8%
Non-suggestive	2	2.8%
<b>MRI brain (n=16)</b>		
Suggestive	16	22.8%
Non-suggestive	0	0.0%
<b>Gene Expert</b>		
Positive	4	5.7%
Negative	66	94.3%

The outcome of patients was assessed post-therapy. Only 21 (30.0%) cases had a complete recovery after TBM whereas 17 (24.2%) recovered with sequelae. High mortality was noted in the study with 10 (14.2%) deaths whereas 22 (31.4%) cases were lost to follow-up. (Figure I)



**Figure I: Disease outcome.**

There were a total of 17 (24.2%) cases that developed various sequelae. There were 7 (10.0%) children with paraplegia/hemiplegia, 4 (5.7%) had epilepsy, 3 (4.3%) children had mental retardation. Two (2.8%) cases developed blindness post TBM whereas 1 (1.4%) children had deafness. (Figure II)



**Figure II: Distribution of disease sequelae (n=17)**

## Discussion

In this study, a poor clinicopathological profile of children with TBM was noted. The majority of the cases were in stage II and stage III of TBM. The outcome of patients post-therapy was also found quite compromised with only 30.0% of cases completely recovered and a similar proportion was lost to follow-up. The mortality was quite high and a significant number of children had recovery with sequelae. Evidence suggests that TBM is a

childhood disease and is associated with severe morbidity.<sup>3</sup> Despite the availability of effective chemotherapy, the tumor-blastoma virus's (TBM) ongoing devastation in both developed and developing countries is cause for concern.

In the current study, the most frequent clinical symptoms were fever, irritability/rigidity, seizures, vomiting, headache, and loss of appetite. Initially, most children develop headache, fever, irritability, and vomiting in TBM.<sup>8</sup> Bang et al also noticed similar clinical features in their cases of TBM with fever, headache, weight loss, fits, neck stiffness, and nuchal rigidity as most common.<sup>9</sup> Similar findings on the clinical features of TBM have been reported by many others as well.<sup>3</sup> The symptoms of TBM in this study are continuous with previously reported by various investigators.<sup>9,10</sup> It is noteworthy and well documented that the clinical onset of TBM is mostly acute, sub-acute, or of a gradual nature.<sup>11</sup>

The present study found the majority of cases having CSF findings suggestive of TBM, decreased WBCs and glucose levels, and a raised protein level as well as the predominance of lymphocytosis. Bang ND and colleagues also noted CSF confirmation in three-fourth of their study cases, similar to the current study findings.<sup>9</sup> A study by Rohlwink UK and colleagues also noticed CSF confirmation of TBM in close to half of their study cases. Though the definitive TBM diagnosis depends upon the detection of tubercle bacilli in the CSF, the abnormalities of TBM are well-differentiated in untreated patients.<sup>12</sup>

The radiological confirmation with CT scan brain and MRI brain also confirmed the severity of the disease in the majority of the current study patients, and this was found in continuation with previous literature. CT or MRI brain reveals thickening of meninges and their intense enhancement, some cases present with ventricular enlargement, and many others are seen with hydrocephalus and infarcts, however, MRI clearly and better highlights the infarcts than CT image.<sup>3,13</sup> Many other investigators have also reported the high utility of imaging with CT and MRI in children with TBM.<sup>14,15</sup>

In this study, approximately one-third of cases recovered completely, while many were lost to follow-up, and the number of deaths and recovery with sequelae was also high. Similar outcomes of TBM patients have been witnessed before as well. It was reported that children diagnosed with an advanced stage of the disease have poor outcomes.<sup>13</sup> Well and colleagues observed severe sequel in 19% of their cases and 13% mortality, which is

comparable to our findings.<sup>16</sup> An Indian cohort study followed TBM children for up to 7 years after illness and discovered that 46% had poor school performance and behavioural issues, 22.0% had a neurological deficit, and 15.0% had fits.<sup>17</sup> Another study by Miftode et al also witnessed high rates of neurological deficits in their TBM cases.<sup>18</sup>

In this study, the most frequent sequelae were paraplegia/hemiplegia, mental retardation, and epilepsy. Previous researchers have also established TBM sequelae as one of the main manifestations of the disease.<sup>19,20</sup> Since neurological deficit is one of the key outcomes of children after TBM, there is a need to develop strategies to alert parents and guardians and community healthcare workers in the country to pick early signs of TBM in suspected children.<sup>21</sup> The way forward is to detect and treat TBM as early as possible, as late presentation in severe stages has severe morbidity, mortality, and neurological deficit.<sup>21</sup> Another strategy could be to maintain the cohorts of the children with TBM and monitoring changes in their lives later on and preventing the severity of the side effects such as irritability, low quality of life, and dependencies.

## Conclusion

This study highlights that TBM presents with poor clinical and pathological state in the advanced stage of the disease. The therapy outcome is also not satisfactory as high mortality rates and sequelae pose a constant challenge.

This study has many advantages; First, a reasonable retrospective cohort of children with TBM was screened and analyzed. Secondly, a detailed review of their clinical presentation, diagnostics, and clinical outcome was quantified. The limitations of the study are built in its observational nature and retrospective visit of the medical records of children, however, keeping in view the importance of TBM, the advantages clearly outplay the limitations.

## References

1. Srivastava G, Faridi MMA, Gupta SS. Tubercular infection in children living with adults receiving Directly Observed Treatment Short Course (DOTS): a follow-up study. *BMC Infect Dis* 2020; 20: 720 <https://doi.org/10.1186/s12879-020-05449-x>
2. Haq SU, Hussain M, Krishin J, Abbasi S. Risk factors of tuberculosis in children. *Ann Pak Inst Med Sci* 2010;6(1):50-4.
3. Chin JH. Tuberculous meningitis: Diagnostic and therapeutic challenges. *Neurol Clin Pract*. 2014;4(3):199-205. <https://doi.org/10.1212/CPJ.0000000000000023>
4. Gopaldaswamy R, Dusthacker VNA, Kannayan S, Subbian S. Extrapulmonary Tuberculosis-An Update on the Diagnosis, Treatment and Drug Resistance. *J Respiration*. 2021; 1(2): 141-164 <https://doi.org/10.3390/jor1020015>
5. Jullien S, Ryan H, Modi M, Bhatia R. Six months therapy for tuberculous meningitis. *Cochrane Database of Systematic Reviews* 2016; 9: CD012091. <https://doi.org/10.1002/14651858.CD012091.pub2>
6. Aulakh R, Chopra S. Pediatric Tubercular Meningitis: A Review. *J Pediatr Neurosci*. 2018;13(4):373-382. [https://doi.org/10.4103/JPN.JPN\\_78\\_18](https://doi.org/10.4103/JPN.JPN_78_18)
7. Israni AV, Dave DA, Mandal A, Singh A, Sahi PK, Das RR. Tubercular meningitis in children: clinical, pathological, and radiological profile and factors associated with mortality. *J Neurosci Rural Pract*. 2016;7:400-4 <https://doi.org/10.4103/0976-3147.181475>
8. Daniel BD, Grace GA, Natrajan M. Tuberculous meningitis in children: Clinical management & outcome. *Indian J Med Res*. 2019;150(2):117-130. [https://doi.org/10.4103/ijmr.IJMR\\_786\\_17](https://doi.org/10.4103/ijmr.IJMR_786_17)
9. Bang ND, Caws M, Truc TT, Duong TN, Dung NH, Ha DT et al. Clinical presentations, diagnosis, mortality and prognostic markers of tuberculous meningitis in Vietnamese children: a prospective descriptive study. *BMC Infectious Diseases*. 2016; 16(1):1-0. <https://doi.org/10.1186/s12879-016-1923-2>
10. Ramzan A, Nayil K, Asimi R, Wani A, Makhdoomi R, Jain A, et al. Childhood tubercular meningitis: An institutional experience and analysis of predictors of outcome. *Pediatr Neurol*. 2013;48:30-5 <https://doi.org/10.1016/j.pediatrneurol.2012.09.004>
11. van Toorn R, Solomons R. Update on the diagnosis and management of tuberculous meningitis in children. *Semin Pediatr Neurol*. 2014;21:12-8. <https://doi.org/10.1016/j.spen.2014.01.006>
12. Rohlwink UK, Figaji A, Wilkinson KA, Horswell S, Sesay AK, Deffur A, Enslin N, . Tuberculous meningitis in children is characterized by compartmentalized immune responses and neural excitotoxicity. *Nat Commun* 2019; 10: 3767 <https://doi.org/10.1038/s41467-019-11783-9>
13. Dian S, Hermawan R, van Laarhoven A. Brain MRI findings in relation to clinical characteristics and outcome of tuberculous meningitis. *PLoS One*.

- 2020;15(11):e0241974  
<https://doi.org/10.1371/journal.pone.0241974>
14. Li S, Nguyen IP, Urbanczyk K. Common infectious diseases of the central nervous system-clinical features and imaging characteristics. *Quant Imaging Med Surg.* 2020;10(12):2227-2259.  
<https://doi.org/10.21037/qims-20-886>
  15. Chiang SS, Khan FA, Milstein MB, Tolman AW, Benedetti A, Starke JR, et al. Treatment outcomes of childhood tuberculous meningitis: A systematic review and meta-analysis. *Lancet Infect Dis.* 2014;14:947-57  
[https://doi.org/10.1016/S1473-3099\(14\)70852-7](https://doi.org/10.1016/S1473-3099(14)70852-7)
  16. van Well GT, Paes BF, Terwee CB, Springer P, Roord JJ, Donald PR, et al. Twenty years of pediatric tuberculous meningitis: A retrospective cohort study in the Western Cape of South Africa. *Pediatrics.* 2009;123:e1-8  
<https://doi.org/10.1542/peds.2008-1353>
  17. Mohan J, Rakesh PS, Moses PD, Varkki S. Outcome of children with tuberculous meningitis: A prospective study from a tertiary care centre in Southern India. *Int J Community Med Public Health.* 2016;4:220-3  
<https://doi.org/10.18203/2394-2612.20160303>
  18. Miftode EG, Dorneanu OS, Leca DA, Juganariu G, Teodor A, Hurmuzache M, et al. Tuberculous meningitis in children and adults: A 10-year retrospective comparative analysis. *PLoS One.* 2015;10:e0133477.  
<https://doi.org/10.1371/journal.pone.0133477>
  19. Manyelo CM, Solomons RS, Walz G, Chegou NN. Tuberculous meningitis: pathogenesis, immune responses, diagnostic challenges, and the potential of biomarker-based approaches. *J. Clin. Microbiol.* 2021; 59(3): e01771-20.  
<https://doi.org/10.1128/JCM.01771-20>
  20. Ducomble T, Tolksdorf K, Karagiannis I, Hauer B, Brodhun B, Haas W, et al. The burden of extrapulmonary and meningitis tuberculosis: An investigation of national surveillance data, Germany, 2002 to 2009. *Euro Surveill.* 2013;18 pii: 20436.  
<https://doi.org/10.2807/ese.18.12.20436-en>
  21. Mihailidou E, Goutaki M, Nanou A, Tsiatsiou O, Kavaliotis J. Tuberculous meningitis in Greek children. *Scand J Infect Dis.* 2012;44:337-43.  
<https://doi.org/10.3109/00365548.2011.639030>