

Outcome of proximally based medial hemi-soleus muscle flap for coverage of soft tissue defects in leg

Muhammad Naveed Shahzad¹, Ahmad Ali², Muhammad Hussain³, Naheed Ahmed⁴

¹⁻³Senior Registrar Plastic Surgery

⁴Professor & Head of Deptt Plastic Surgery

Pakltalian Modern Center, Nishtar Medical University, Multan

Author's Contribution

¹Drafting the work or revising it critically for important intellectual content

¹⁻³Substantial contributions to the conception or design of the work; or the acquisition, analysis, or interpretation of data for the work.

⁴Final approval of the version to be published

Funding Source: None

Conflict of Interest: None

Received: April 07, 2019

Accepted: November 16, 2019

Address of Correspondent

Dr. Muhammad Naveed Shahzad
Senior Registrar Plastic Surgery
Pakltalian Modern Burn Center,
Nishtar Medical University,
Multan

drmuhammaad@gmail.com

ABSTRACT

Objective: To review the use of proximally based medial hemi-soleus muscle flap for exposed soft tissue defects in middle third leg.

Methodology: The descriptive (retrospective) study was conducted in Pakltalian Modern Burn Center, Multan from January 2014 to December 2018. Retrospective data was collected among patients where medial hemi-soleus muscle flap was done. This series depicts the use of medial hemi-soleus muscle flap in Patients having small to medium sized defects (ranged from 4-12 cm length and 2-8 cm width). The flap was done in most of the cases after 3 weeks. Patients having small to medium sized defects in middle third of tibia (Defect size ranged from 4-12 cm length and 2-8 cm width) were included in the study. Variables of study were recipient-site issues, donor-site management, complications, and outcomes. Descriptive analysis was done.

Results: Among 96 patients, 84 were males and 12 were females and their age ranged between 15-57 years. Out of 96 flaps 90 flaps survived completely, four had major flap loss and two flaps completely lost. Major complication was infections in flap followed by graft loss and haematoma.

Conclusion: Proximally based medial hemi-soleus muscle flap is a reliable flap easy to do and easy to follow.

Keywords: Medial hemi-soleus muscle flap, complication, infection

Cite this article as: Shahzad MN, Ali A, Hussain M, Ahmed N. Outcome of proximally based medial hemi-soleus muscle flap for coverage of soft tissue defects in leg. *Ann Pak Inst Med Sci.* 2019; 15(3): 103-107.

Introduction

The incidence of Long bone fractures is 11.5 per 100,000 population per year and males are more commonly affected.^{1,2} Most of the tibial length and about 1/3rd of the circumference of the tibia is subcutaneous that makes tibia most commonly affected long bone associated with soft tissue defects leading to exposure of tibia.³ Early plastic surgical intervention for coverage of exposed bone by soft tissue significantly reduces the risk of infection, nonunion and subsequent amputation.⁴ Defects of the middle third of tibia are unique and for the coverage of this area few methods are devised like simple relaxing-calf incision, local random flaps, crossleg pedicle flaps, local muscle flaps, fasciocutaneous flaps and

microvascular free flaps. The microvascular free tissue transfer is a remarkable advancement in the field of plastic and reconstructive surgery and has become gold standard for the reconstruction of defects in lower limb. However, free tissue transfer is always limited by expertise of operating surgeons and infrastructure that facilitate free flap preoperative, operative and postoperative flap monitoring and rehabilitation. Therefore, it is important to devise local options for the reconstruction of middle-third lower extremity defects if possible.^{5,6,7} For middle third of tibia soleus muscle flap is available which has a robust blood supply. The soleus muscle a flat, broad muscle of the calf of the leg lying just inferior to the gastrocnemius muscle is classified as type II according to the classification of Mathes and

Nahai. The posterior tibial artery is a major pedicle and the secondary pedicles are the perforating branches of posterior tibial artery. Being the prime ankle plantar flexor and ankle stabilizer soleus works with gastrocnemius muscle and share Achilles tendon with gastrocnemius for insertion. The whole soleus flap has been described for the defect coverage however it definitely weakens the planter flexion. Tobin GR described the use of hemisoleus muscle flap.⁸ Many authors described usefulness and reliability of hemisoleus muscle flap. Medial hemisoleus muscle flap is described as better option as it has a greater arc of rotation because of geometric orientation and only partially sacrifices ankle flexion.

In this study, we reviewed the use of proximally based hemisoleus muscle flap for exposed middle third leg defects, recipient-site issues, donor-site management, complications, and outcomes.

Methodology

This retrospective descriptive case series was done on 96 consecutive cases of hemisoleus muscle flap, at the PakItalian Modern Center, Multan from January 2014 to December 2018. After approval of the study protocol from the Institutional Ethical Committee, patients with having defects of Soft tissue loss extending beyond a middle third of leg, patients having pre-existing vascular problems, patients with a damaged vascular pedicle of muscle, patients with severe systemic co-morbidities, i.e. uncontrolled DM, uncontrolled hypertension were excluded.

From the departmental medical record system, we retrieved the records of patients and gathered the information regarding the demographic, diagnostic, and clinical data (i.e age and sex, cause of defect, mechanism of injury, size and location of the defects, time since injury, exposure of bone or tendons, presence of chronic osteomyelitis, any co-morbid conditions, postoperative course regarding wound-healing difficulties, flap loss and walking limitations) were noted. Pre and post-operative photographs and radiographs were also evaluated. Most of these patients were referred to our department from orthopedic department after bony fixation. The patients with open fractures were admitted to accident and emergency department PakItalian Modern Center, Multan. After stabilization of the patient, tetanus prophylaxis, and broad-spectrum antibiotics were given. Reductions of bones were done by orthopedic department after Non-viable tissue debridement. Serial debridement was needed if tissue viability was uncertain. When the

wound bed was clean, flap coverage was done, within 72 to 96 hours following initial injury in our setup. However, in some cases we had to perform flap at later dates because of unstable patient or unfavorable wound. In another set of patients where trauma was not the cause (like burn, tumor excision, scar excision) reconstruction was done later. Preoperative documentation of function of the remaining muscles of the leg especially the flexion at ankle joint, the sensation of sole, documentation of pulsations at dorsalis pedis and posterior tibial was done. However when there was history of trauma at popliteal region and / or absence or weakness in comparison with the other side we requested the CT angiogram to get the patency of vascular tree prior to surgery. The CT angiogram was also advised in patients with history of peripheral vascular disease. In patients with history of DVT (deep venous thrombosis) we got the Doppler studies and in case of incompetence and/or established disease we tried simpler methods by closing wound through lateral relaxing incisions.

All the patients who were booked for flap surgery underwent preoperative anesthesia assessment and accordingly received either general or spinal anesthesia. Patients were positioned in the supine position. Pneumatic tourniquet was applied in all the patients. After sterile preparation, the entire extremity was prepared and leg was kept fully exposed. Placement site of incision was made in a line 2 cm medial to the medial edge of the tibia; wide assess was achieved through this incision to the medial hemisoleus muscle. Dissection was done distally as it was easier and safer to separate and made a safe plane between gastrocnemius and soleus muscle and between soleus and most posterior set of muscles. Distally identification of the secondary vascular pedicles was done and their sacrifice was needed to get good arc of rotation. Median raphe between the two heads of muscles were identified and the muscle was divided longitudinally along the median raphe. The medial belly of soleus muscle was transferred to the Wound. Primary closure was sometimes possible however mostly muscles were grafted. A suction drain was placed. A very light dressing was done. Tie-over dressing was not done over the muscle as it obstructed the monitoring of muscle. However, small ooze from muscle surface for the couple of hours was noted but later it became dry. On 6th postoperative day most of the patients were discharged except those who had infections. Stitches were removed on 14th postoperative day. Follow up protocol was on weekly basis for first month thereafter bi-weekly for next month. A final follow-up visit was

done after two months. Data analysis was done using SPSS 20 version. Frequency and percentage tables are added.

Results

Over a period of 4 years a total of 96 patients were operated using soleus muscle flap to reconstruct the defect. Among 96 patients, 84 were males and 12 were females and their age ranged between 15-57 years. Demographics of patients are given in Table I.

Table I: Demographic details

		Number	%
Age range (n=96)	15-20 years	3	3.12%
	21-30 years	39	40.62 %
	31-40 years	42	43.75%
	41-50 years	4	4.16%
	> 51 years	8	8.33%
Gender	Male	84	87.5 %
	Female	12	12.5 %
Mechanism	open fracture	80	83.33 %
	Electrical burn	5	5.20 %
	Tumor excision	1	1.04%
	Sinus Chronic osteomyelitis	1	1.04%
	Scar excision	1	1.04%
	Fire arm injuries	2	2.08%
Time Interval between initial injury and flap coverage	Within 1 week	20	20.8%
	1 – 2 Week	14	14.6%
	2 – 3 Week	10	10.4%
	More than 3 weeks	52	54.2%
Min time = 3 days			
Max time=4 months			

In our series the major cause of pre-tibial soft tissue loss was open fractures following road traffic accidents, followed by 5 patients of electrical burns. One patient had closed fracture and developed osteomyelitis and got debridement and flap coverage. Soft tissue defects were also a result of unstable scar excision following initial burn injury in 1 patient and after tumor (Squamous cell cancer) excision from mid tibial region in 1 cases. Two cases were done following gunshot (fire arm injuries). Regarding time interval between the date of injury or excision surgery and the date of flap surgery, most of the operations were done after 3 weeks of the injury. The maximum delay is 4 months and the earliest coverage was done soon after the wound was made after excision

of scar and tumor. In all the cases, wound swab culture was done immediately before operation. Out of 96 patients, 60 (62.50%) pre-operative culture positive cases and during post-operative phase 20 (20.33) cases remained culture positive. (Table II)

Table II: Organism found in culture

Pre- operative phase		Operative phase	
Pseudomonus	21	Pseudomonus	4
E. Coli	12	E. Coli	0
Proteus	8	Proteus	0
Mixed (predominant Staphylococcal sp.)	20	Mixed (predominant Staphylococcal sp.)	16
Total culture positive	61	Total culture positive	20
Total culture negative	34	Total culture negative	76

Whenever there was clinical evidence of infection we requested for Post-operative wound swab culture. There were no symptoms and signs of infection in postoperative period in the 31 cases where pre-operative wound swab culture were negative. The total flap were found viable In 90 (93.75%) cases. In the rest of 6 cases, two cases had more than 50% flap loss i.e: major or almost complete flap failure which was detected at 5th POD for which initially we had to do debridement and in both cases we had to do cross-leg flap. In these two cases with major flap loss purulent discharge, infection, and wound dehiscence was found.

In 4 cases of marginal flap loss or less than 50% flap necrosis was found and treated with debridement and flap advancement. Infection of skin graft donor site on in our study but it was easily encountered by general wound care strategies. Postoperative complications are presented in table III.

Table III: Flap survival and post-operative complication.

Flap survival	
Complete flap survival	90 cases
Major flap loss ~ 50 %	2 cases
Complete flap loss > 50 %	4 cases
Postoperative course & complications	
Hematoma	10 cases
Venous congestion	1 cases
Wound dehiscence	6 cases
Superficial epidermolysis	2 cases
Infection	20 cases
Skin graft loss	16 cases
Donor Site Infection	25 cases

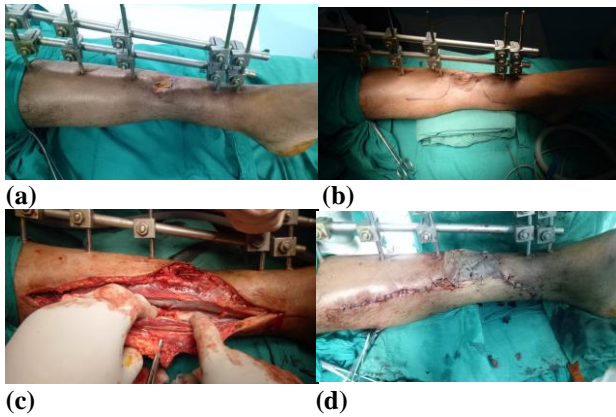


Figure 1: (a) External fixture applied by orthopedic department. (b) marking (c) distal perforators (d) split thickness graft

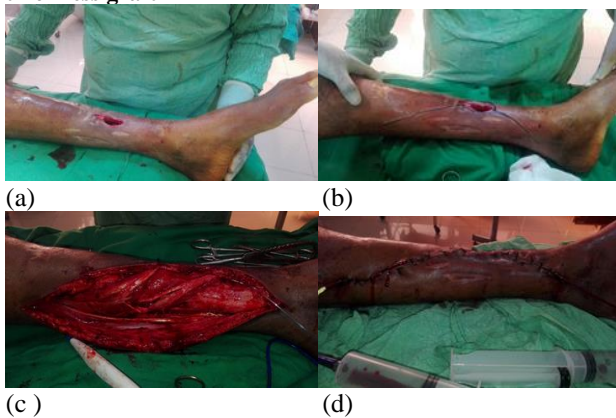


Figure 2: (a) Chronic osteomyelitis sinus after closed fracture tibia. (b) marking. (c) proximally based medial hemisoleus muscle flap (d) closure

Discussion

The soft tissue injury of middle third of leg is challenging however in local options soleus flap has become work horse. The present study demonstrated the effectiveness of the soleus muscle flap for coverage of pretibial soft tissue defect of middle third of leg. Management of open fractures following high energy injuries requires a multidisciplinary approach and plastic surgeon is responsible for the reconstruction of soft tissue injuries. Over the past two decades the management of lower extremity trauma has evolved to the point where it is possible to salvage lower limb rather than to go for amputation. Now the aim is to achieve a satisfactorily healed wound along with a good functional outcome. Arc of rotation and functional loss are the two reasons for which medial hemisoleus muscle flap is preferred over the whole Soleus muscle flap

In our study younger population is mostly involved, 84 Out of 96 patients were less than 40 years among them the leading cause was open fracture secondary to road

traffic accident. A similar picture is shown in the study of Pu LLQ and Chowdhury et al. where mean age was 37 years and 37.5 years respectively.^{10, 11}

After 3 weeks most of the flaps were done however minimum time for flap coverage was 3 days and the maximum time was 4 months. The time interval between injury and flap coverage in the study of Pu (2006)⁸ was done with 10 days and and Shamsuzzaman et al. (2010), did flap coverage within 5 days of initial trauma.^{13,15} Pollak et al. did most of the flap within 7 days of surgery.¹⁶ In comparison with described studies we did the delayed intervention because of delayed presentation and referral system however it did not become a major issue in outcome of flap results. Flap which were failed in our study were those that had extensive injuries and infections so in planning the flap coverage it is very important to debride the wound in the proper way, saving as much of distal perforators as possible.^{16,17,18} So after the flap failure we adopted this policy and wound swab for culture and sensitivity was sent in every case before and after the surgery. Before surgery initial swab sample was taken from the wound just before the pyodine application. In our patients *Pseudomonas* was the most common organism followed by mixed growth in which *Staphylococcus* became the culprit. After the sensitivity report we treated with appropriate antibiotics accordingly.^{19,20,21} *Pseudomonas* was the most common organism in the study of Caudle & Stern, followed by *Enterococcus* and *Staphylococcus*. However, in another study conducted by Uddin MN found *Staphylococcus* in about half of his case series. We performed post-operative wound swab at 5th day after the operation only in cases where there were purulent discharge and other evidence of wound infection (red, oedematous wound, local pain etc.) that situation was dealt with accordingly.^{22,23,24,25} Dealing with all post-operative complications, we had to do the cross-leg flap, skin re-graft, flap advancement, drainage of seroma / hematoma, debridement of marginal flap necrosis. No death was reported during the period of study and follow up.

Conclusion

Pretibial defect of middle third of leg can be covered effectively by soleus muscle flap with easier dissection and better outcome.

References

1. Court-Brown CM, Caesar B. Epidemiology of adult fractures: a review. *Inj.* 2006;37(8):691-697.

2. Makboul M, Mousa A, Elotiefy M, Ahmed M, Hamdy M. Medial Hemisoleus Muscle Flap in Reconstruction of Soft Tissue Defects of Lower Leg. *Egyptian Journal of Hospital Medicine*. 2019 11;74(6): 1330-1336.
3. Bortolini AC, Fraga DS. Soleus Muscle Flap Application for Reconstruction of the Middle Third of the Leg. *International Journal of Orthoplastic Surgery*. 2018.3;1(3):59-64.
4. Schmidt I. The Proximally and Distally Pedicled Hemisoleus Muscle Flap as Option for Coverage of Soft Tissue Defects in the Middle Third of Lower Leg. *Trauma and Emergency Care*. 2017;2(6):1-4.
5. Pu LLQ. Further Experience with the Medial Hemisoleus Muscle Flap for Soft –Tissue Coverage of a Tibial Wound in the Distal Third of the Leg. *Plast Reconstr Surg* 2008;121(6):2024–2028.
6. Hassanpour SE, Yavari M, Motabar AR. Synchronous Soleus and Reverse Sural Flap for Large Soft Tissue Defect Reconstruction of Leg. *World journal of plastic surgery*. 2018;7(1):12-15.
7. Reddy V, Stevenson TR. Lower Extremity Reconstruction, *Plastic and Reconstructive Surgery* 2008; 121 (4) : 1-7.
8. Pu LLQ. Soft tissue coverage of an open tibial wound in the junction of the middle and distal third of the leg with the medial hemisoleus flap. *Annals of Plastic Surgery* 2006; 56 (6) : 639-643.
9. Choudry U, Moran S, Karcor Z. Soft tissue coverage and outcome of Gustilo IIIB midshaft tibia fracture : A 15 years experience. *Plastic and Reconstructive Surgery* .2008; 122 :479-485.
10. Kasabian AK, Karp NS. Lower extremity reconstruction. In: Grabb and Smith's Plastic Surgery. 6th edn, Thorne CH, Beasley RW, Aston JS, Bartlett SP, Gurtner GC, Sper SL, (eds), Lippincott Williams and Wilkins, Philadelphia. 2007 : 676-688.
11. Mareck CA, Pu LLQ. Refinement of free tissue transfer for optimal outcome in lower extremity reconstruction. *Ann Plast Surg*. 2004; 52 (3): 270-275.
12. Mackenzie DJ, Sayfer AE. Reconstructive surgery: Lower extremity coverage. In: Plastic Surgery, 2nd edn, Mathes SJ, Hentz VR (eds), Saunders Elsevier, Philadelphia. 2006 : 1355- 1381.
13. Hallock GG. Getting most from the soleus muscle. *Ann Plast Surg*. 1996; 36 (2) : 139-146.
14. Westgeest J, Weber D, Dulai SK, Bergman JW, Buckley R, Beaupre LA. Factors associated with development of nonunion or delayed healing after an open long bone fracture: a prospective cohort study of 736 subjects. *Journal of orthopaedic trauma*. 2016;30(3):149-155.
15. Ong SW, Gan LP, Chia DS. The double muscle gastrocnemius-soleus flap in resurfacing large lower limb defects: Modifications and outcomes. *Journal of Orthopaedics*. 2019.[Inprint] <https://www.sciencedirect.com/science/article/abs/pii/S0972978X19301825> doi.org/10.1016/j.jor.2019.06.029
16. Choudry U, Moran S, Karcor Z. Soft tissue coverage and outcome of Gustilo IIIB midshaft tibia fracture: A 15 years experience. *Plastic and Reconstructive Surgery* .2008; 122:479-485.
17. Folse J, Hill CE, Graves ML, Russell GV, Hydrick J, Jones LC, et al. Risk Factors for Kidney Dysfunction With the Use of Gentamicin in Open Fracture Antibiotic Treatment. *Journal of orthopaedic trauma*. 2018 ;32(11):573-578.
18. Bartow-McKenney C, Hannigan GD, Horwinski J, Hesketh P, Horan AD, Mehta S, et al. The microbiota of traumatic, open fracture wounds is associated with mechanism of injury. *Wound Repair and Regeneration*. 2018 ;26(2):127-135.
19. Karbalaekhiani A, Saied A, Heshmati A. Effectiveness of the gastrosoleus flap for coverage of soft tissue defects in leg with emphasis on the distal third. *Arch Bone Jt Surg*. 2015;3(3):193-197.
20. Kauffman CA, Lahoda LU, Caderna PS, Kuzon WA. Use of soleus muscle flap for coverage of distal third tibial defect. *J reconstr Microsurg*. 2004; 20(8) : 593- 597.
21. Neale HW, Stern PJ, Kerilein JG, Gregorj RO, Webster KL. Complicatopn of muscle-flap transposition for traumaticdefect of legs. *J Plast Reconstr Surg*. 1982; 72 (4) : 512-515.
22. Chittora R, Mishra SM. Fasciocutaneous flap in reconstruction of lower extremity. *Katmundu University Medical Journal*. 2004; 2 (4) : 344-348.
23. Huston JJ, Dajicioglu D, Oeltjen J, Panthaki Z, Armstrong M. The treatment of Gustilo IIIB fracture with application of antibiotic spacer, flap and sequential distraction osteogenesis. *Ann Plast Surg*. 2010; 64 (5) : 541-552.
24. Khundkar SH, Kalam MA. Distally based fasciocutaneous flaps for reconstruction of defects with lower leg. *J Bangladeshb Coll Phys Surg*. 1996; 14 : 3-9.
25. Park J, Lee S, Son D. Safety of Elevation from Superficial Fascial Plane versus Traditional Deep Fascial Plane for Flap Elevation in a Porcine Model. *Archives of Hand and Microsurgery*. 2018;23(2):99-109.