

Acute high dose reprotoxic effects of bisphenol-A on the testicles of adult rodents

Rabia Sajjad Toor¹, Kanwal Sharif², Hafiza Sadia Ahmed³, Tahrim Ansar⁴

¹ Assistant Professor, Department of Anatomy, Sahara Medical College, Narowal

² Senior Demonstrator, Azra Naheed Medical College, Lahore

³ Senior Demonstrator, Amna Inayat Medical College, Lahore

⁴ Associate Professor Anatomy, Niazi Medical & Dental College, Sargodha

Author's Contribution

¹Substantial contributions to the conception or design of the work; or the acquisition, analysis, or interpretation of data for the work.

^{2,3}Drafting the work or revising it critically for important intellectual content

⁴Final approval of the version to be published

Funding Source: None

Conflict of Interest: None

Received: September 6, 2019

Accepted: February 27, 2020

Address of Correspondent

Dr. Rabia Sajjad Toor

Assistant Professor, Department of Anatomy, Sahara Medical College, Narowal

Email: dr_rabiasajjad@yahoo.com

ABSTRACT

Objectives: To evaluate the acute effects of high dose of bisphenol-A (BPA) induced in the testicles of adult rats.

Methodology: An Experimental study was conducted at Anatomy Department, University of Health Sciences, Lahore, from January 2015 to December 2015.

Twelve adult Wistar albino rats were weighed and divided into three groups of four rats each. Group A (control) was given corn oil (2ml/kg/day). Group B (BPA-100) was given BPA 100mg/kg/day dissolved in corn oil (2ml/kg/day). Group C (BPA-200) was given BPA 200mg/kg/day dissolved in corn oil (2ml/kg/day). The animals were sacrificed on the 8th day after weighing. Testis were weighed and fixed in Buoin's solution. Johnson scoring was done in H&E stained slides. Basement membrane integrity was observed in PAS stained slides.

Results: Group A rats showed normal parameters. Group B (BPA-100) showed a significant decrease in Johnson score and an increase in basement membrane disruption while the changes in body weight of animals and paired weight of testis was statistically insignificant. Group C (BPA 200) rats died within 3-4 days and the experiment was limited to two groups.

Conclusion: The results of the present study indicate that a high dosage of Bisphenol A in rats causes significant disruption of the testicular histology and proves to be a significant reprotoxin even with a short duration of exposure.

Key Words: Bisphenol A, Testicles, Johnson score, Basement membrane.

Cite this article as: Toor RS, Sharif K, Ahmed HS, Ansar T. Acute high dose reprotoxic effects of bisphenol-A on the testicles of adult rodents. *Ann Pak Inst Med Sci.* 2019; 15(3): 138-142.

Introduction

Endocrine disrupting chemicals (EDCs) are becoming an uprising environmental factor leading to an increase in deteriorative reproductive health effects and infertility.¹ The xeno-estrogenic effects of EDCs are mainly associated with reproductive health problems and involve the estrogen signaling pathways.² Interference with androgen signaling pathways is another mechanism associated with male reproductive developmental and functional health problems.³ Testicular dysgenesis syndrome includes a range of male reproductive problems such as cryptorchidism, poor semen quality and

testicular carcinoma that are increasing partially due to the increased exposure of environmental pollutants.⁴

Bisphenol A (BPA) is a plasticizer and one of the EDCs with production at high volumes worldwide annually along with increasing levels in the environment.⁵ Its estrogen mimicking property was first reported in 1936.⁶ It is employed in the production of polycarbonate plastic and resins, which are further used for making water bottles, dental sealants, the lining of food and beverage cans. BPA monomers tend to migrate from its lining resins of food and beverage cans into food especially in temperate environments.⁷

Male reproductive health is targeted and deteriorated by this pollutant.⁸ BPA has a wide range of adverse male reproductive health effects in the developmental period as well as adulthood by changing hormonal balance or direct dystrophic effects on testicular tissue.⁹ It also affects Leydig cells directly and via hypophysial-gonadal axis to decrease serum testosterone production and release.¹⁰

BPA has weak estrogenic effects and it acts both on the surface and nuclear estrogenic receptors. It also causes changes in the expression of hormone binding proteins.¹¹ Oxidative stress is another mechanism by which it has deteriorative effects on the process of spermatogenesis even at low doses.¹²

Chronic low dose exposure of this pollutant has been well studied but acute high dose effects have been well investigated. This study has been conducted to determine the acute high dose effects of BPA on testicular tissue and to determine the tolerance of rodents to high oral doses of this compound.

Methodology

Twelve rats of age 6 to 8 weeks and weight 180-200gm were procured from the animal house of the University of Health Sciences, Lahore. The initial body weight was noted while marking the animals with numbers and randomly dividing them into three groups of four rats each. The animals were allowed to acclimatize for 2 days before experiments. Free access to water and food was provided at room temperature ($24^{\circ}\pm 5^{\circ}$) and normal conditions of humidity ($45\% \pm 5\%$).

The dosage was administered at 10 am daily.

Group A (control) was given corn oil 5ml/kg/day orally for 7 days

Group B (BPA-100) was given BPA 100mg/kg/day in corn oil orally for 7 days

Group C (BPA-200) was given BPA 200mg/kg/day in corn oil orally

At the end of the experimental duration, the animals were weighed before sacrifice. The pair of testes of each rat was dissected out, weighed and fixed in Bouin's solution.

Tissue processing was done and 4 μ m thick sections were cut. H&E stained sections were examined to assess the Johnson score of tubules. PAS staining was done to examine the basement membranes of seminiferous tubules.

The data were entered and analyzed using SPSS version 21. Quantitative parameters like body weights paired weight of testes and Johnson scoring was analyzed using the Independent-sample t test and two-tailed significance was calculated between both groups. The qualitative parameters like basement membrane integrity was analyzed using Pearson Chi-square test and association of the histological parameter and groups was assessed. Frequencies and percentages were given for the parameter of basement membrane and mean with standard deviation and standard error of means were given for the body weight, testicular weight and Johnson score. P-value ≥ 0.05 was considered statistically significant.

Results

Animals of group A were healthy. Group B and C rats showed irritability and decreased appetite which was more marked in the higher dose group C. Group C rats developed marked fatigue and loss of appetite before they expired after 3-4 days of intervention and investigation proceeded with two groups. The rats of group C showed signs of diarrhea, muscles paralysis and difficult respiration and died within 2 to 3 hours of development of these symptoms.

The initial body weight of animals in both groups started from the same level. The mean initial weight of group A rats was 182gm \pm 3.162 and that of group B was 185gm \pm 4.242 ($p=0.300$). There was no significant difference in mean final body weight of both groups ($p=0.475$). Mean final body weight of group A was 190.875gm \pm 4.028 and that of group B was 186.975gm \pm 9.416 (Table I).

There was no statistical difference between both groups regarding this parameter ($p=0.499$). Mean paired weight of gonads in group A was 2.445gm \pm 0.171 and that of group B was 2.367gm \pm 0.130 (Table II).

Table 1: Independent-sample t Test showing two-tailed significance of difference between mean Final body weights of animals in groups A and B.

Parameter of Study	Groups	Mean \pm SD	Standard Error of Mean (SEM)	Mean Difference	p-value
Final Body Weight of Rats (gm)	A	190.875 \pm 4.028	2.014	3.900	0.475
	B	186.975 \pm 9.416	4.708		

*p-value ≤ 0.05 is considered statistically significant

Table II: Independent-sample t Test showing two-tailed significance of difference between mean Paired weight of testes of animals in groups A and B.

Parameter of Study	Groups	Mean \pm SD	Standard Error of Mean (SEM)	Mean Difference	p-value
Paired Weight of Testes (gm)	A	2.445 \pm 0.171	0.086	0.775	0.499
	B	2.367 \pm 0.130	0.065		

*p-value ≤ 0.05 is considered statistically significant

Table III: Independent-sample t Test showing two-tailed significance of difference between mean Johnson score of seminiferous tubules in groups A and B.

Parameter of Study	Groups	Mean \pm SD	Standard Error of Mean (SEM)	Mean Difference	p-value
Johnson Score of Seminiferous tubules	A	9.612 \pm 0.281	0.140	3.297	0.001*
	B	6.315 \pm 0.177	0.088		

*p-value ≤ 0.05 is considered statistically significant

Statistically significant difference was observed in this parameter ($p=0.001$). Mean Johnson score of group A was 9.612 ± 0.281 and that of group B was 6.315 ± 0.177 (Table III, Figure 1-2)

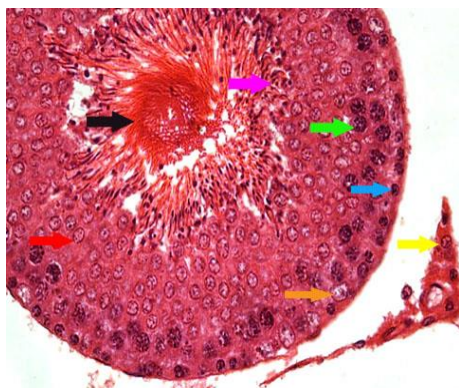


Figure 1. Photomicrograph of seminiferous tubule of group A with Johnson score 10. Sertoli cells (orange arrow), Leydig cells (yellow arrow), Spermatogonia (blue arrow), Primary spermatocytes (green arrow), Round spermatids (red arrow), Elongated spermatids (pink arrow) and Spermatozoa in lumen (black arrow) are identified clearly. H&E. X400

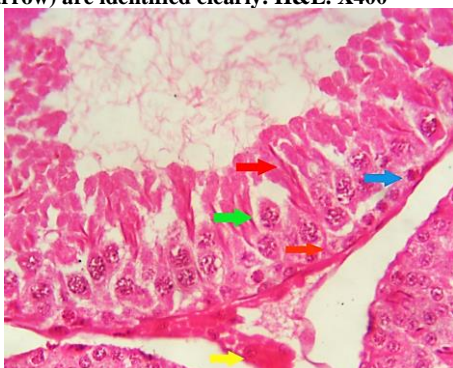


Figure 2. Photomicrograph of seminiferous tubule of group B with Johnson score of 6. Sertoli cells (orange arrow), Leydig cells (yellow arrow), Spermatogonia (blue arrow), Primary spermatocytes (green arrow) and desquamating spermatids (red arrow) are identifiable. H&E. X400

Basement membrane integrity was disturbed at a significant level in the treatment group ($p=0.014$). Out of 64 sections of seminiferous tubules assessed in group A, 53 were intact (82.8%) and 11 were disrupted (17.2%). In group B, 41 sections showed intact basement membranes (64.1%) and 23 were disrupted (35.9%) from 64 sections observed Table IV (Figure 3-4)

Table IV: Pearson Chi Square Test showing number and percentages of intact and disrupted basement membranes in groups A and B.

Groups	Basement membrane n/%age within groups		Total	p-value
	Intact	Disrupted		
A	53/ 82.8%	11/ 17.2%	64/ 100%	0.014*
B	41/ 64.1%	23/ 35.9%	64/ 100%	

*p-value ≤ 0.05 is considered statistically significant

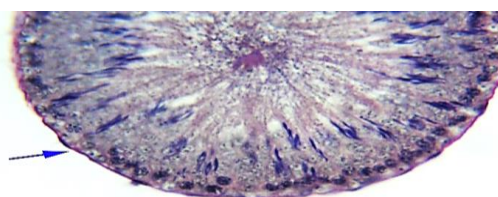


Figure 3: Photomicrograph of seminiferous tubule of group A showing Intact basement membrane and normal seminiferous epithelium (blue arrow). PAS with hematoxylin. X400

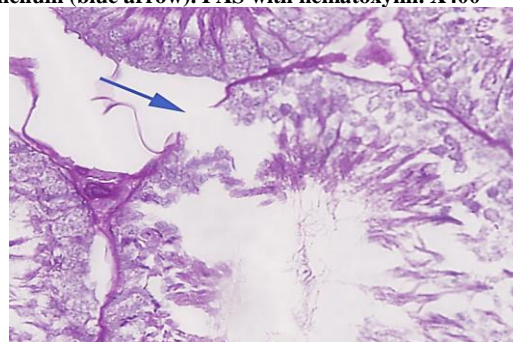


Figure 4. Photomicrograph of seminiferous tubule of group B showing Disrupted basement membrane along with sloughing of seminiferous epithelium (blue arrow). PAS with hematoxylin. X400

Discussion

Male infertility has increased worldwide.¹³ BPA, a synthetic carbon based plasticizer is now well known for its hazardous effects on reproductive health in humans as well as animals.¹⁴ Male reproductive organs are mainly affected and disruption of testicular steroidogenesis and spermatogenesis are the primary adverse effects of this contaminant.¹⁵

Previous studies have shown that the xenoestrogenic effects of BPA are attributed to its affinity to the estrogenic as well as androgenic receptors. Adverse effects at low and high doses, on spermatogenesis and leydig cells, have also been documented via increased oxidative stress¹⁶. The current study was designed to assess the acute high dose effects of BPA on testicular tissue of rodents.

In the present study, BPA had a negative effect on the behavior and appetite but the bodyweight of animals treated insignificantly decreased in the short period of intervention. Morgan et al (2014) also reported no change in body weight when they treated rats with BPA (25mg/kg/day).¹⁷ Low (0.05mg/l) and high (5mg/l) doses of BPA given in drinking water for a longer duration showed decreased body and testicular weights in male prepubertal rats.¹⁸

There was insignificant decrease in the paired weight of testis that is also attributed to the short duration of the experiment. A statistically significant decrease was observed in animals after exposure to BPA (25mg/kg/day) for a month. BPA decreased the testosterone levels by decreasing the number of leydig cells while it also caused a decrease in tubular diameter, both factors contributing to the decrease in testicular weight.¹⁹

Spermatogenesis is a sensitive process affected by exposure to drugs, radiation and pollutants.²⁰ In the present study, Johnson score of the BPA treated animals significantly decreased as compared to control. Studies have shown that doses of BPA as low as 20 µg/kg/day and 200µg/kg/day have been reported to cause negative changes in seminiferous epithelium and disruption of Blood Testis Barrier (BTB). BPA has been shown to directly target the junctions of Sertoli cells, making cells of different stages of spermatogenesis vulnerable to the toxic effects.²¹

Increased oxidative stress has been attributed to the mechanism of toxicity produced by pollutants like

bisphenols²². The present study showed significant disruption of basement membranes in rats exposed to BPA. Basement membrane damage results from protein oxidation and lipid peroxidation during high oxidative stress state.²³ The same mechanism may be attributed to the results of our study.

In this study, a high dose of BPA has shown significant toxic effects on testicular histology. As the plastic and paper industries are significantly growing in developed as well as developing countries, there are increased environmental concentrations of synthetic xenoestrogenic compounds like bisphenols and phthalates. Occupational exposure leads to higher levels of contamination through all routes.²⁴ The data regarding BPA exposure and adverse effects is still deficient and needs more investigation.

Conclusion

The testicular histology was markedly deteriorated by exposure to the high dose of BPA as shown by a significant decrease in Johnson score and increased disruption in basement membranes of the seminiferous tubules. Hence, it is concluded that high dose exposure of BPA given for short duration causes testicular toxicity in albino rats.

References

1. Cederroth CR, Zimmermann C, Nef S. Soy, phytoestrogens and their impact on reproductive health. *Mol Cell Endocrinol*. 2012; 355:192-200.
2. Rosenfeld CS, Cooke PS. Endocrine disruption through membrane estrogen receptors and novel pathways leading to rapid toxicological and epigenetic effects. *J Steroid Biochem Mol Biol*. 2019; 187: 106-117. doi: 10.1016/j.jsbmb.2018.11.007.
3. Sakkiah S, Wang T, Zou W, Wang Y, Pan B, Tong W, Hong H. Endocrine disrupting chemicals mediated through binding androgen receptor are associated with diabetes mellitus. *Int J Environ Res Public Health*. 2018; 15(1): 25. doi: 10.3390/ijerph15010025.
4. Xing JS, Bai ZM. Is testicular dysgenesis syndrome a genetic, endocrine or environmental disease, or an unexplained reproductive disorder? *Life*. 2018; 194: 120-129. doi: 10.1016/j.lfs.2017.11.039.
5. Patisaul HB. Achieving clarity on bisphenol A, brain and behavior. *J Neuroendocrinol*. 2019; 7:12730. <http://doi.org/10.1111/jne.12730>.
6. Dodds EC, Lawson W. Synthetic Oestrogenic agents without the phenanthrene nucleus. *Nature* 1936; 137(3476):996.
7. Jennifer C, Hartle, Navas-Acien, Lawrence RS. The consumption of canned food and beverages and urinary bisphenol A concentrations in NHANES 2003-2008.

- Environ Res. 2016; 150: 375-382. doi: 10.1016/j.envres.2016.06.008.
8. Helal EGA, Badawi MMM, Soliman MG, Abdel-kawi NA, Fadel HAE and Abozaid NMG. Physiological and histopathological studies on Bisphenol-A compound as xenoestrogen in male albino rats. *Egyptian J. Hosp. Med.* 2013; 50:127-136.
 9. Norazit A, Mohamad J, Razak SA, Abdulla MA, Azmil A and Mohd MA. Effect of soya bean extract, Bisphenol A and 17 β -estradiol on the testis and circulating levels of estradiol among peripubertal juvenile male Sprague Dawley rats. *Sains Malaysiana*.2012; 41(1): 63-69.
 10. Nanjappa MK, Simon L, Akingbemi BT. The industrial chemical bisphenol A interferes with proliferative activity and development of steroidogenic capacity in rat leydig cells. *Biol Reprod.* 2012; 86(5): 135. doi: 10.1095/biolreprod.111.095349.
 11. Yoon K, Kwack SJ, Kim HS, Lee BM. Estrogenic endocrine disrupting chemicals: molecular mechanisms of actions on putative human diseases. *J Toxicol Environ Health B Crit Rev*, 2014; 17(3): 127-74.
 12. Sabeti P, Pourmasumi S, Rahiminia T, Akyash F, Talebi AR. Etiologies of sperm oxidative stress. *Int J Reprod Biomed*.2016; 14: 231-240.
 13. Kumar N, Singh AK. Trends of male factor infertility, an important cause of infertility: A review of literature. *J Hum Reprod Sci.* 2015; 8(4): 191-196. doi: 10.4103/0974-1208.170370.
 14. Vitku J, Sosvorova L, Chlupacova T, Hampl R, Hill M, Sobotka V, Heracek J, et al. Differences in bisphenol A and estrogen levels in the plasma and seminal plasma of men with different degrees of infertility. *Physiol Res.* 2015; 64: 303-311.
 15. Munir B, Qadir A, Tahir M. Negative effects of bisphenol A on testicular functions in albino rats and their abolitions with Tribulus Terristeris L. *Braz J Pharm Sci*, 2017; 53(3):e00104. <http://dx.doi.org/10.1590/s2175-9790217000300104>.
 16. Shafei A, Ramzy MM, Hegazy AI, Husseny AK, El-Hadary UG, Taha MM, et al. The molecular mechanisms of action of the endocrine disrupting chemical bisphenol A in the development of cancer. *Gene J.* 2018; 647:235-243. doi:10.1016/j.gene.2018.01.016.
 17. Morgan AM, El-ballal SS, El-bialy BE and El-borai NB. Studies on the potential protective effect of cinnamon against Bisphenol A and octylphenol induced oxidative stress in male albino rats. *Toxicol Reprod.* 2014; 92-101. Doi: 10.1016/j.toxrep.2014.04.003.
 18. Anteur HY, Bendahmane M, Khan NA. Perinatal exposure to bisphenol A affects body weight and the reproductive function of Wistar rats. *J Appl Environ Biol Sci.* 2016; 6(3): 1-8.
 19. Munir B, Qadir A and Tahir M. Negative effects of BPA on testicular functions in albino rats and their abolitions with tribulus terristeris L. *Braz J Pharm Sci.* 2014; 53(3):e00104.
 20. Mortazavi M, Salehi I, Alizadeh H, Vahabian M, Roushonde AM. Protective effect of antioxidants on sperm parameters and seminiferous epithelium in high fat-fed rats. *J Reprod Infertil.* 2014; 15: 22-28.
 21. Ogo FM, Siervo GEML, Goncalves GD, Cecchini R and Guarnier FA. Low doses of Bisphenol A can impair postnatal testicular development directly without affecting hormonal or oxidative stress levels. *Reprod Fertil Dev*, 2017. <http://dx.doi.org/10.1071/RD16432>.
 22. Hulak M, Gazo I, Shaliutina A and Linhartova P. In vitro effects of Bisphenol A on the quality parameters, oxidative stress, DNA integrity and adenosine triphosphate content in starlet spermatozoa. *Comparative Biochem Physiol PartC: Toxicol Pharmacol*, 2013; 158: 64-71.
 23. Turkmen R, Akosman MS, Demirel HH. Protective effect of n-acetylcysteine on MK-801-induced testicular oxidative stress in mice. *Biomed Pharmacother.* 2019; 109: 1988-93. doi: 10.1016/j.biopha.2018.09.139.
 24. Ribeiro E, Ladeira C, Viegas S Occupational exposure to bisphenol A: a reality that still needs to be unveiled. *Toxics.* 2017; 5(3):22. doi: 10.3390/toxics5030022.