

# Diagnostic Accuracy of Fine Needle Aspiration Cytology (FNAC) in Salivary Gland Tumors

Farah Farhan<sup>1</sup>, Maria Ilyas<sup>2</sup>, Sadia Muneer<sup>3</sup>, Abeer Zahra<sup>4</sup>, Zainab Niazi<sup>5</sup>,  
Mariya Farooq<sup>6</sup>

<sup>1</sup>Associate Professor Oral Pathology Rawal Institute of Health Sciences, Islamabad

<sup>2</sup>Assistant Professor Oral Pathology, CMH Lahore, <sup>3</sup>Assistant Professor Oral Pathology, NUMS, Islamabad

<sup>4</sup>Demonstrator Oral Pathology Rawal Institute of Health Sciences, Islamabad

<sup>5</sup>Associate Professor Oral Pathology, Islamabad Dental Hospital, Islamabad

<sup>6</sup>Demonstrator Oral Pathology Margalla Institute of Health Sciences, Islamabad

## Author's Contribution

<sup>1</sup>Conception and idea acquisition of data, <sup>2</sup>Data Analysis, <sup>3</sup>Results interpretation, <sup>4</sup>Editing and drafting, <sup>5</sup>Critical Revision, <sup>6</sup>Final approval of the study to be published

Funding Source: None

Conflict of Interest: None

Received: February 02, 2024

Accepted: May 27, 2024

## Address of Correspondent

Dr. Zainab Niazi

Associate Professor Oral Pathology, Islamabad Dental Hospital, Islamabad  
dr.zainabniazi@gmail.com

## ABSTRACT

**Objectives:** To evaluate the diagnostic accuracy of fine needle aspiration cytology (FNAC) by comparing its findings with the gold standard histological features of salivary gland lesions.

**Methodology:** This retrospective study was conducted at the Department of Histopathology, Islamabad Medical and Dental Hospital (IMDC), from January 2023 to December 2023, patients presenting with salivary gland swellings. Fifty-seven patients having salivary gland swelling were included on which both histological and cytological evaluation had been done. Twenty cases were excluded because either they had lack of correlation between FNAC and histology or on view of inadequate material. All the patients were clinically evaluated clinically and FNAC was done using 10ml disposable syringe and 23/24-gauge needle without using local anesthesia. The histopathology of the surgical specimens and cytology of the FNAC specimens were compared, and the sensitivity, specificity, positive predictive value (PPV), and negative predictive value (NPV) were evaluated.

**Results:** On FNAC, 37 cases were diagnosed cytologically, as 9 cases identified malignant and 28 as benign. Histopathological examination confirmed 9 malignant cases and 25 benign cases, whereas 3 cases were classified as false positive. The specificity and sensitivity of FNAC were 75% and 94%, respectively. Overlapping cytological features, heterogeneity, and unsampled areas were the primary factors contributing to false-positive.

**Conclusion:** This study showed that salivary gland FNA cytology is a valuable diagnostic technique for salivary gland lesions, however due to great variation in pleomorphic adenoma, the samples must be confirmed by histopathological features.

**Keywords:** Fine needle aspiration cytology; Salivary gland neoplasm; Histopathology; Cytology

Cite this article as: Farhan F, Ilyas M, Muneer S, Zahra A, Niazi Z, Farooq M. Diagnostic Accuracy of Fine Needle Aspiration Cytology (FNAC) in Salivary Gland Tumors. *Ann Pak Inst Med Sci.* 2024; 20(3):346-350. doi. 10.48036/apims.v20i3.1054

## Introduction

Histopathology is confirmed for the gold in the final diagnosis and staging of salivary gland lesions. However, fine needle aspiration cytology (FNAC) is widely used method for preoperative diagnosis because of its valuable and safe methodology.<sup>[1]</sup> It aids in widely categorizing salivary gland lesions into inflammatory, non-neoplastic,

and neoplastic conditions—differentiating between benign and malignant. Accurate FNAC diagnosed results have significant therapeutic implications and help clinicians in managing patient.<sup>[2-4]</sup> Despite it is being widely used, cytopathologic evaluation can be prone to pitfalls and challenging. The diagnostic validity and accuracy of FNAC depends on the quality of the aspirate and the experience and technical knowledge of the

cytopathologist. The diagnostic difficulties are enhanced by the heterogeneity of salivary gland tumors, which shows a wide variety of histopathologic features.<sup>[5-7]</sup> The basic aim of our study was to evaluate the diagnostic reliability, specificity, sensitivity of FNAC in differentiating inflammatory, benign, and malignant salivary gland lesions by correlating FNAC results with histopathological diagnosis. Additionally, we analyzed the reasons of discrepancies in results in salivary gland lesions by comparing results cytologic smears with the histopathologic findings of resected specimens. Fine needle aspiration cytology (FNAC) is a valuable diagnostic tool for evaluating salivary gland tumors.

## Methodology

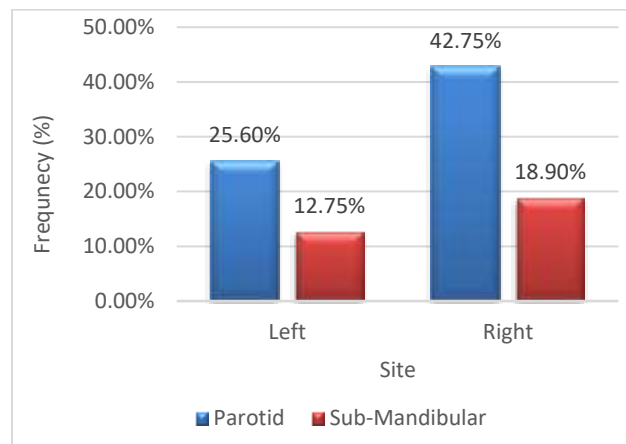
The present study was conducted at Islamabad Medical and Dental Hospital over the duration of a year, from January 2023 to December 2023 retrospectively. Ethical approval for the study was granted by the Institutional Review Board (IRB) under ID: SP20/123/J. We selected 57 cases of salivary gland swelling, having both cytological and histological examinations. Two cases were excluded due to scant aspirate on Fine Needle Aspiration Cytology (FNAC), and another 18 cases had either only cytology or histology reports available so were excluded. Consequently, the study included 37 cases for which cyto-histological correlation was performed. All patients underwent a thorough clinical evaluation followed by clinical examination, history-taking and hematological and radiological investigations. FNAC was conducted on various sites of the salivary gland swellings using a 10 ml disposable syringe and a 23/24-gauge needle, without the use of local anesthesia. FNAC smears were prepared in two ways: air-dried smears were stained with Leishman stain, while wet smears fixed in 95% ethyl alcohol were stained using either Papanicolaou stain or Hematoxylin and Eosin stain. The study also involved comparing the histopathological findings of the surgical specimens with the cytological results of the FNAC specimens. The sensitivity, specificity, positive predictive value (PPV), negative predictive value (NPV), and overall accuracy of FNAC in differentiating between benign and malignant conditions were evaluated.

The data analysis tool used was IBM Corp.'s SPSS Base version 20.0, located in Armonk, NY. The sensitivity, specificity, positive predictive value (PPV), negative predictive value (NPV), and overall accuracy of FNAC were assessed using recognized statistical methods in order to differentiate benign from malignant disease. While frequencies and percentages were used to represent

the qualitative factors, mean and standard deviation were used to represent the quantitative data. To compare the qualitative variables, we used the chi-square test.

## Results

Out of 37 subjects who underwent FNAC (Fine Needle Aspiration Cytology) of their salivary glands during the study, 27.16% were between the ages of 21 and 30, while 72.84% were between the ages of 31 and 40. The age group with the highest prevalence was 31-40 years (72.84%), followed by the 21-30 years group (17.28%). The average age of the patients was  $18.97 \pm 36.89$  years, ranging from 21 to 40 years. The gender distribution included 27 females (72.9%) and 10 males (27%), resulting in a male-to-female ratio of 1:1.33. The parotid gland was the most frequently observed site for FNAC, accounting for 66.5% of cases, followed by the submandibular gland with 33.5%. FNAC was more commonly performed on the right side (61.65%) compared to the left side (38.35%), as shown in Figure 1.



**Figure 1. FNAC frequency based on laterality and location (N=37)**

On continued follow up 1 patients developed recurrence from grade 3. (Table II) all the patients were followed up for 1 to 3 years.

## Discussion

Of head and neck malignancies, 3% are primary salivary gland tumors<sup>[8,9]</sup> These histologically complicated tumors are mostly benign. Histopathological features in malignant salivary gland tumors, especially those that are well-differentiated, overlap with those of benign tumors. The main course of treatment for cancers of the salivary glands is surgery; adjuvant radiation and/or chemotherapy may be used based on the tumor's histologic type, grade, and stage. The most significant diagnostic technique is FNAC,

**Table I: Distribution of salivary gland lesions based on location.**

FNAC Diagnosis	Site		Total No in both glands (%)
	Sub-Mandibular N 11 (%)	Parotid N 26 (%)	
Acute Sialadenitis	1 (2.70%)	2 (5.41%)	3 (8.11%)
Pleomorphic Adenoma	3 (8.11%)	15 (40.54%)	18 (48.65%)
Chronic Sialadenitis	1 (2.70%)	1 (2.70%)	2 (5.40%)
Warthin Tumor	2 (5.41%)	3 (8.11%)	5 (13.52%)
Acinic Cell Carcinoma	1 (2.70%)	1 (2.70%)	2 (5.40%)
Mucoepidermoid Carcinoma	3 (8.11%)	3 (8.11%)	6 (16.22%)
Adenoid Cystic Carcinoma	0 (0.00%)	1 (2.70%)	1 (2.70%)
Carcinoma ex Pleomorphic	0 (0.00%)	0 (0.00%)	0 (0.00%)
<b>Total</b>	<b>11 (29.73%)</b>	<b>26 (70.27%)</b>	<b>37 (100%)</b>

**Table II: Results of FNAC and diagnosis by biopsy and their association.**

Cytologic Diagnosis	Histologic Diagnosis							
	Total	Pleomorphic Adenoid Frequency (n)	Adenoid Cystic Carcinoma Frequency (n)	Mucoepidermoid Carcinoma Frequency (n)	Warthin Tumor Frequency (n)	Acinic Cell carcinoma Frequency (n)	Acute Sialadenitis Frequency (n)	Chronic Sialadenitis Frequency (n)
Acute Sialadenitis	3	1	0	0	0	0	0	0
Pleomorphic adenoma	18	15	0	0	1	0	0	0
Chronic Sialadenitis	2	1	0	1	1	0	0	0
Warthin tumor	5	0	0	0	5	0	0	0
Adenoid cystic carcinoma	2	0	1	1	0	0	0	0
Mucoepidermoid carcinoma	6	0	2	4	0	0	0	0
Acinic cell carcinoma	1	0	0	0	0	1	0	0
Warthin tumor	5	0	0	0	5	0	0	0
Adenoid cystic carcinoma	2	0	1	1	0	0	0	0

**Table III: Accuracy, Specificity and Sensitivity of FNAC.**

Sensitivity= $\frac{\text{number of true positives}}{\text{number of true positives} + \text{number of false negatives}}$	94%
Accuracy= $\frac{\text{number of true positives} + \text{number of true negatives}}{\text{number of true positives} + \text{false positives} + \text{false negatives} + \text{true negatives}}$	84%
Specificity= $\frac{\text{number of true negatives}}{\text{number of true negatives} + \text{number of false positives}}$	75%
Negative predictive value= $\frac{\text{number of true negatives}}{\text{number of true negatives} + \text{number of false negatives}}$	71%
Positive predictive value = $\frac{\text{number of true positives}}{\text{number of true positives} + \text{number of false positives}}$	86%
Sensitivity= $\frac{\text{number of true positives}}{\text{number of true positives} + \text{number of false negatives}}$	94%

particularly in the preoperative diagnosis of large SG primary tumors. It is more accurate in diagnosing SG lesions than physical examination and imaging techniques, with a range of 80-95% [10-13]. FNAC is used to attempt to

determine if the mass is benign, malignant, neoplastic, or inflammatory.

It should be reported if a malignancy diagnosis is made, regardless of whether the tumor is a primary salivary gland tumor or a metastatic one. The grade (low/high) of a primary salivary gland tumor should be indicated if one is found. As a result, it is possible to distinguish between masses that need surgery and those that do not, to partially select the type of operation, and to partially prevent treatment-related difficulties for the patient [14-20].

According to the preoperative assessment of primary salivary gland tumors in our study, FNAC has a sensitivity, specificity, and accuracy of above 94%, 75% and 84% respectively. Alphas et al. reported a 90–95% accuracy rate for FNAC, while Al Salamah's study reported an 89% accuracy rate. [21-23] Preoperative FNAC demonstrated a sensitivity of 59.09%, specificity of 97.85%, accuracy of 93.75%, positive predictive value of 76.47%, and negative

predictive value of 95.2% for the detection of malignancy, according to a study by Yıldız et al. [24] The differences between our study and others, such as the study by Yıldız et al., can be attributed to several factors. These include variations in study populations and tumor types, differences in the expertise and techniques of cytopathologists, and discrepancies in study design and statistical methods.

In the present study, age group of 2rd and 3rd decade had more salivary gland lesions and female predominance was found which was 1:1.33 in other studies similarly females were outnumbered. [25] Parotid gland was found in 67.35% cases and is similar to other studies. There were 24 (58.65%) benign lesions and 10 (19.2%) malignant cases, these incidences were also comparable to other studies. [26] 18 out of 37 cases diagnosed as pleomorphic adenoma on FNAC, 15 out of 37 cases were correctly confirmed by histopathology and remaining three case were false positive. Errors may be due to sampling technique as from nonrepresentative areas with inflammation and pathological changes. FNAC samples taken from pleomorphic adenoma shows epithelial type cells with chondromyxoid background. This is similar to other studies as 50% and 21.6% cases were of pleomorphic adenoma. [27] There were 5 cases of sialadenitis confirmed on histopathology, while no case of sialadenitis were conformed on histopathology. Out of five cases of sialadenitis, two were confirmed as pleomorphic, one as Warthin's tumor and one was mucoepidermoid carcinoma on histopathology. In present study cyto-histological correlation of for chronic sialadenitis was 62.5% compared to 90% and 81.8% in other studies. [28] The diagnostic sensitivity of FNAC in detecting malignant disease was 97.4% and specificity was 71.1 Sampling error can lead to increase number of false negative and false positive FNAC results and decrease in diagnostic accuracy. In our study there were 3 (4.34%) false positive cases, one was on FNAC diagnosed as acute sialadenitis and other two were pleomorphic adenoma on FNAC. These cases have varied complex and overlapping morphological features which make the diagnosis difficult.

## Conclusion

In conclusion, we found a good relation between final histology and FNAC, however there is a challenge in diagnoses of pleomorphic adenoma as it has wide variations in cytology and when aspirated inadequately and therefore either immunohistochemical or repeat

aspiration should be advised before embarking on therapeutic excision.

## References

1. Maleki Z, Miller JA, Arab SE, Fadda G, Bo P, Wise O, Rossi ED. "Suspicious" salivary gland FNA: risk of malignancy and interinstitutional variability. *Cancer Cytopathol.* 2018;126:94-100. <https://doi.org/10.1002/cncy.21939>
2. Akhter J, Hirachand S, Lakhey M. Role of FNAC in the diagnosis of salivary gland swellings. *Kathmandu Univ Med J.* 2018;6:204-208.
3. Singh Nanda KD, Mehta A, Nanda J. Fine-needle aspiration cytology: a reliable tool in the diagnosis of salivary gland lesions. *J Oral Pathol Med.* 2012;41:106-112. <https://doi.org/10.1111/j.1600-0714.2011.01069.x>
4. Silva WP, Stramandinoli-Zanicotti RT, Schussel JL, Ramos GH, Ioshi SO, Sassi LM. Accuracy, sensitivity and specificity of fine needle aspiration biopsy for salivary gland tumors: a retrospective study from 2006 to 2011. *Asian Pac J Cancer Prev.* 2016;17:4973-4976.
5. Shetty A, Geethamani V. Role of fine-needle aspiration cytology in the diagnosis of major salivary gland tumors: a study with histological and clinical correlation. *J Oral Maxillofac Pathol.* 2016;20:224-229. <https://doi.org/10.4103/0973-029X.185899>
6. Sarkar A, Sharma N, Sharma S. Fine needle aspiration cytology utility in salivary gland tumor diagnosis. *Indian J Otolaryngol Head Neck Surg.* 2017;69:147-154. <https://doi.org/10.1007/s12070-016-0982-4>
7. Gudmundsson JK, Ajan A, Abtahi J. The accuracy of fine-needle aspiration cytology for diagnosis of parotid gland masses: a clinicopathological study of 114 patients. *J Appl Oral Sci.* 2016;24:561-567. <https://doi.org/10.1590/1678-775720160214>
8. Alsanie I, Rajab S, Cottom H, Adegun O, Agarwal R, Jay A, Graham L (2022). Distribution and Frequency of Salivary Gland Tumours: An International Multicenter Study. *Head and neck pathology*, 16(4), 1043-1054. <https://doi.org/10.1007/s12105-022-01459-0>
9. Young A, Okuyemi OT. Malignant Salivary Gland Tumors. [Updated 2023 Jan 12]. In: StatPearls. Treasure Island (FL): StatPearls Publishing; 2024
10. Farahani SJ, Baloch Z. Retrospective assessment of the effectiveness of the Milan system for reporting salivary gland cytology: A systematic review and meta-analysis of published literature. *Diagn Cytopathol.* 2019;47:67-87. <https://doi.org/10.1002/dc.24097>
11. Rossi ED, Faquin WC, Baloch Z, et al. The Milan System for Reporting Salivary Gland Cytopathology: Analysis and suggestions of initial survey. *Cancer Cytopathol.* 2020;125:757-66. <https://doi.org/10.1002/cncy.21898>
12. Wu HH, Alruwaili F, Zeng BR, et al. Application of the Milan System for Reporting Salivary Gland Cytopathology: A Retrospective 12-Year Bi-institutional Study. *Am J Clin Pathol.* 2019;3;151:613-21. <https://doi.org/10.1093/ajcp/aqz006>

13. Kaushik R, Bhatia K, Sarin H, et al. Incorporation of the Milan system in reporting salivary gland fine needle aspiration cytology-An insight into its value addition to the conventional system. *Diagn cyto.* 2020;48:17-29. <https://doi.org/10.1002/dc.24321>
14. Das DK, Petkar MA, Al-Mane NM, Sheikh ZA, Mallik MK, Anim JT. Role of fine needle aspiration cytology in the diagnosis of swellings in the salivary gland regions: A study of 712 cases. *Med Princ Pract.* 2019;13:95-106. <https://doi.org/10.1159/000075637>
15. Daneshbod Y, Daneshbod K, Khademi B. Diagnostic difficulties in the interpretation of fine needle aspirate samples in salivary lesions: Diagnostic pitfalls revisited. *Acta Cytol.* 2009;53:53-70. <https://doi.org/10.1159/000325085>
16. Ashraf A, Shaikh AS, Kamal F, Sarfraz R, Bukhari MH. Diagnostic reliability of FNAC for salivary gland swellings: A comparative study. *Diagn Cytopathol.* 2020;38:499-504. <https://doi.org/10.1002/dc.21211>
17. David O, Blaney S, Hearp M. Parotid gland fine needle aspiration cytology: An approach to differential diagnosis. *Diagn Cytopathol.* 2017;35:47-56. <https://doi.org/10.1002/dc.20581>
18. Das DK, Anim JT. Pleomorphic adenoma of salivary gland: To what extent does fine needle aspiration cytology reflect histopathological features? *Cytopathol.* 2019;16:65-70. <https://doi.org/10.1111/j.1365-2303.2004.00208.x>
19. Aydoğdu İ, Saltürk Z, Uyar Y, Yıldırım G, Çakır Ç, Ataç E. The Role of Fine Needle Aspiration Biopsy in the Diagnosis of Parotis Masses. *Eur Arch Med Res.* 2015;31:175-8. <https://doi.org/10.5222/otd.2015.1014>
20. Özdamar K, Aydın S, Altaş, B, Yücebaş K, Altınay S, Öğreden Set, Faruk et al. The importance of fine needle aspiration biopsy in parotid gland masses. *Praxis of ORL.* 2020;3:20-4. <https://doi.org/10.5606/kbbu.2015.26121>
21. Grasl S, Kadletz L, Janik S, Riedl A, Erlacher B, Formanek M, Grasl MC, et al. Fine-needle aspiration cytology and intraoperative frozen section in parotid gland tumour surgery: a retrospective multicenter analysis of 417 cases. *Clin Oto-laryngol.* 2019;44:461-5. <https://doi.org/10.1111/coa.13314>
22. Alphas HH, Eisele DW, Westra WH. The role of ne needle aspiration in the evaluation of parotid masses. *Curr Opin Otolaryngol Head Neck Surg.* 2006;14:62-6. <https://doi.org/10.1097/01.moo.0000193184.38310.0a>
23. Al Salamah SM, Khalid K, Khan IAR, et al. Outcome of surgery for parotid tumours: 5-Year Experience of a General Surgical Unit in a Teaching Hospital. *ANZ J Surg.* 2005;75:948-52. <https://doi.org/10.1111/j.1445-2197.2005.03580.x>
24. Yıldız S, Seneldir L, Tepe Karaca C, Zor Toros S. Fine-Needle Aspiration Cytology of Salivary Gland Tumors Before the Milan System: Ten Years of Experience at a Tertiary Care Center in Turkey. *Medeni Med J.* 2021;36:233-40. <https://doi.org/10.5222/MMJ.2021.90912>
25. Singh N, Mehdratta KS, Satyanand. Study of salivary gland tumors. *Indian Journal of Surgery* 2020;193-206.
26. Khandekar MM, Kavatkar AN, Patankar SA, Bagwan IB, Puranik SC, Deshmukh SD, FNAC of salivary gland lesions with histopathological correlation. *Indian Journal of Otolaryngology and Head and Neck Surgery* 2006;58:246-48. <https://doi.org/10.1007/BF03050831>
27. Cristallinin EG, Ascani S. Fine Needle aspiration biopsy of salivary gland. *Acta Cytol*;41:1421-25. <https://doi.org/10.1159/000332853>
28. Cajulis RS, Gokaslan ST. Fine needle aspiration biopsy of the salivary glands. *Acta Cytol*;2021:1412-19. <https://doi.org/10.1159/000332852>