

# The Functional Outcome in Patients Undergoing Wide Decompressive craniectomy to remove acute subdural haematoma with Dural Stabs versus Open Dural Flap

Ahsan Ali, Abdul Razaque Mari, Muhammad Aslam Shaikh

## Author's Affiliation

Department of neurosurgery DUHS  
civil hospital Karachi  
Department of neurosurgery PUMHS  
Nawabshah  
Department of neurosurgery SMBBU  
Larkana

## Author's Contribution

<sup>1</sup> Data collection and manuscript formatting  
<sup>2</sup> write the manuscript and data analysis  
<sup>3</sup> Data analysis and manuscript writing

## Article Info

Received: March 26, 2017  
Accepted: Aug 11, 2017

## How to Cite this Manuscript

Ali A, Mari AR, Shaikh MA. The Functional Outcome in Patients Undergoing Wide Decompressive craniectomy to remove acute subdural haematoma with Dural Stabs Versus Open Dural Flap. *Ann. Pak. Inst. Med. Sci.* 2017; 13(3):267-271

Funding Source: Nil  
Conflict of Interest: Nil

**Address of Correspondence**  
Dr. Abdul Razaque Mari  
dr.sajidarain786@gmail.com

## ABSTRACT

**Objective:** To determine the functional outcome in patients undergoing wide decompressive craniectomy to remove ASDH with "Dural Stabs" versus "Open Dural flap".

**Subject and Methods:** This comparative study was conducted at department of Neurosurgery, Dow University of Health Sciences, Civil Hospital Karachi with one year duration from 2013 to 2014. All the patients with acute subdural haematoma and associated intracranial brain injury such as contusion, brain edema and/or subarachnoid hemorrhage were included in the study. Patients were randomly allocated into two groups. Thirty-seven patients were treated with Dural Stabs and 37 were treated with Open Dural Flap. Under general anesthesia, after all aseptic measures, a skin incision at the side of hematoma was given. Free bone flap craniectomy via 4 or 5 burr hole, followed by evacuation of hematoma with either "Dural Stabs" or "Open Dural Flap" was done. Postoperatively all patients was shifted to surgical ICU. Functional outcome i.e. either "Good Outcome" or "Poor Outcome" was measured at the time of discharge by G.O.S. All the data was recorded on the proforma.

**Results:** Total 74 cases were studied; thirty-seven patients were treated with Dural Stabs and 37 were treated with Open Dural Flap. The mean age of the patients was 34.73±9.54 years. Out of 74 cases, there were 45(60.8%) male and 29(39.2%) female. The good functional outcome was significantly high in dural stabs as compare to open dural flap (86.5% vs. 32.4%; p=0.0005). Furthermore, age group of 21 to 40 years had a good outcome as compared to the age group of 41 to 60 years but it was non-significant.

**Conclusion:** It is concluded that stabling the dura at intervals decompressed the underlying edematous brain slowly with better results, in comparison to the open dural flap.

**Key Words:** Decompressive craniectomy, Open Dural flap, ASDH

## Introduction

Severe traumatic brain injury, TBI (G.C.S <8), is associated with mortality rates of more than 50%<sup>1</sup>. The cause of death is herniation due to raised intracranial pressure (brain swelling). Patients with severe traumatic brain injury have raised intracranial pressure requiring surgical decompressive

craniectomy, which is being performed with increasing frequency<sup>2</sup>. According to the DECRA trial (Decompressive Craniectomy in Patients with Severe Traumatic Brain Injury), 70% in the craniectomy group had an unfavorable outcome<sup>3</sup>. This is coupled with delayed neurological

recovery<sup>4</sup>. Raising of the dural flap after decompressive craniectomy is done to gain intracranial extra space as the intracranial volume is fixed because of the inelastic skull. This technique reduces the ICP to <20mm Hg<sup>5</sup>. Abdul R B et al showed that the technique of dural stabs after wide decompressive craniectomy had 43.3% good recovery, 6.6% moderate disability, 11.6% severe disability, 16.6% vegetative state and mortality of 21.6%. This compared to 11.6% good recovery in dural flap group with 6.6% moderate disability, 8.3% severe disability, 13.3% vegetative state and 60% mortality<sup>6</sup>. Decompressive craniectomy for traumatic Acute Subdural hematoma still has major mortality rate and the advent of new surgical techniques to reduce mortality will certainly be rewarding. The rationale of this study is to compare the technique of Dural Stabs with Open Dural flap as an alternative to evaluate the functional outcome as either "Good Outcome" or "Poor Outcome" according to Glasgow Outcome Scale, in patients with a Traumatic acute subdural hematoma. This will not only help in pre-operative counseling but also in minimizing the mortality and morbidity in a developing country like ours.

## Methodology

**Setting:** Department of Neurosurgery, Dow University of Health Sciences, Civil Hospital Karachi.

**Duration of study:** One year from 2013 to 2014

**Sample size:** Using two population proportion formula, good outcome according to G.O.S with 50% prevalence of "dural Stab" group and 18% prevalence of "dural flap"<sup>6</sup> with 95% confidence interval, 10% power of the test, the sample size calculation is 31\* per group. The total sample size being 74.

**Inclusion criteria:**

- Patients between 20 to 60 years old.
- Either sex male or female.
- GCS score 3-8 at the time of presentation in E.R.
- Injury within 6hrs of presenting in E.R.
- Criteria on Ct scan:
- Volume of Acute Sub Dural Hematoma >30ml, calculated by the formula (dimensions in mm): 0.5 x transverse diameter x anteroposterior diameter x craniocaudal diameter
- Midline shift >5mm

- Acute subdural haematoma and associated intracranial brain injury such as contusion, brain edema and/or subarachnoid hemorrhage.

**Exclusion Criteria:**

- Patients on anti-coagulants and presenting with a non-traumatic hematoma.
- Patients with G.C.S >8.
- Patients presenting with injury more than 6hrs.

**DATA COLLECTION PROCEDURE:** Patients with CT scan diagnosed traumatic intracranial Acute Sub Dural Hematoma, fulfilling the inclusion criteria were admitted through emergency in the Neurosurgery Department, D.U.H.S, Civil Hospital Karachi. They were included in the study taking informed consent from the patient if he/she is able to do it. Data regarding age, sex, presentation in E.R within 30min to 6hrs of trauma, G.C.S at the time of admission and post-op, midline shift and hematoma volume on CT scan, underlying secondary brain injury and outcome measured in G.O.S at discharge was collected. After resuscitation in the E.R, CT Scan Brain Plain as per NICE (National Institute for Health and Clinical Excellence) guidelines for CT Scan in Head Injury was done. Conservative management was decided for patients as:

1. G.C.S >8
2. Volume <30ml
3. Midline shift <5mm
4. No focal neurological deficit

All other patients, after blood arrangement, were shifted to the emergency operation theatre. Senior Neurosurgical Resident under the direct supervision of Consultant with minimum 2 years post fellowship experience was performed the surgical procedure. Patients were randomly divided into 2 groups randomly using lottery methods. Under general anesthesia, after all aseptic measures, a skin incision at the side of hematoma was given. Free bone flap craniectomy via 4 or 5 burr hole, followed by evacuation of hematoma with either "Dural Stabs" or "Open Dural Flap" was done. Dural stabs done with a no.11 surgical blade, parallel to dural vessels, 5-8 mm long, 2-2.5 cm apart, knife tip penetrating the dura not more than 0.5mm. Hemostasis was secured and closure of a wound in layers with the bone placed subcutaneously in the abdomen. Postoperatively all patients were shifted to surgical ICU. Functional outcome i.e. either "Good Outcome" or "Poor Outcome" was measured at the

time of discharge by G.O.S as per operational definition. The data was recorded on the proforma.

**DATA ANALYSIS PROCEDURE:** Data was analyzed by SPSS version 20. Mean  $\pm$  standard deviation were employed for numerical variables, whereas frequencies and percentages were computed for categorical variables. Chi-square test was applied to observe proportion of "Outcome" between both groups. P-value  $\leq 0.05$  was considered statistically significant.

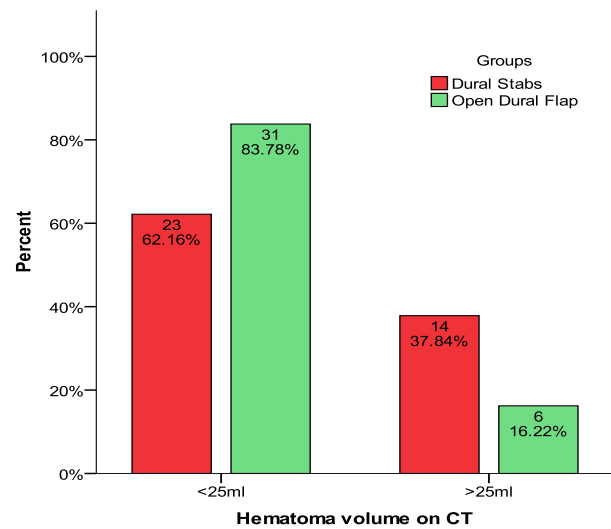
## Results

Total 74 patients presented with acute subdural hematoma were studied. Thirty seven patients were treated with Dural Stabs and 37 were treated with Open Dural Flap. The mean age of the patients was  $34.73 \pm 9.54$  years. Out of 74 cases, there were 45(60.8%) male and 29(39.2%) female. Of the dural stab group 35.14% (13/37) patients were in the GCS 3-4 while 45.95% (17/37) were in the open dural flap group had 3 to 4 GCS. Regarding time of injury and surgery of the patients, there were 57(77%) cases whose operated within 6 hours while 17(23%) who operated after 6 hours. **TABLE:1**

Demographic characteristics	Study groups	
	Dural Stabs n=37	Open Dural Flap n=37
Age groups		
41 to 60 Years	27(59.46%)	28(62.16%)
21 to 40 Years	10(40.54%)	09(37.84%)
Gender		
Male	22(59.46%)	23(62.16%)
Female	15(40.54%)	14(37.84%)
GCS		
3-4	13(35.14%)	17(45.95%)
5-6	23(62.16%)	18(48.65%)
7-8	01(02.70%)	02(05.41%)

Rate of hematoma volume on CT, underlying secondary brain injury, midline shaft above 5mm on CT were also observed and presented in figure 1.**FIG:1**

The good functional outcome was significantly high in dural stabs as compare to open dural flap (86.5% vs. 32.4%;  $p=0.0005$ ) as shown in **table 2**.



**FIGURE: 1. HEMATOMA VOLUME ON CT (n=74)**

**TABLE: 2. Comparison of Functional Outcome In Patients Between Groups(N=74)**

Final Outcome	Study groups		Total	P-Value
	Dural Stabs n=37	Open Dural Flap n=37		
Good Outcome	32(86.5%)	12(32.4%)	44(59.5%)	0.0005
Poor Outcome	5(13.5%)	25(67.6%)	30(40.5%)	
<b>Chi-Square = 22.42 ; df=1</b>				

Good functional outcome was significantly high in dural stabs as compare to open dural flap for 21 to 40 years of age patients while rate of good outcome was high but significant difference was not observed between groups for 41 to 60 years of age patients. Similarly good outcome was significantly high in dural stable groups in male cases ( $p=0.0005$ ) while in female cases this difference was not statistically significant ( $p=0.06$ ) as shown in **table 3**.

Comparison of functional outcome between groups according to hematoma volume on ct, midline shift  $>5$ mm on ct, time between injury and surgery are presented in table 3 which shows good outcome was significant between groups.

**TABLE 3: Comparison of Functional Outcome Between Groups According to Age Groups (N=74)**

Parameters	Final Outcome	Dural Stabs n=37	Open Dural Flap n=37	P-Value
Age groups 21 to 40 Years	Good	23(85.2%)	6(21.4%)	0.0005
	Poor	4(14.8%)	22(78.6%)	
	Total	27	28	
41 to 60 Years	Good	9(90%)	6(66.7%)	0.303
	Poor	1(10%)	3(33.3%)	
	Total	10	09	
Gender Male	Good	20(87%)	4(18.2%)	0.001
	Poor	3(13.0%)	18(81.8%)	
	Total	23	22	
Female	Good	12(85.7%)	8(53.3%)	0.06
	Poor	2(14.3%)	7(46.7%)	
	Total	14	15	
HEMATOMA COLUMN ON CT 3-4	Good	21(91.3%)	11(35.5%)	0.001
	Poor	2(8.7%)	20(64.5%)	
	Total	23	31	
5-6	Good	11(78.6%)	1(16.7%)	0.01
	Poor	3(21.4%)	5(83.3%)	
	Total	14	06	

## Discussion

Injuries of the head are commonest causes of trauma-associated death, being directly linked with round about half of the all trauma-related mortality<sup>8</sup>. Traumatic injury of the brain is the leading source of mortality in peoples having age less than 45 years<sup>9</sup>. According to World Health Organization estimated that traumatic injury of the brain will be the 3<sup>rd</sup> leading reason behind disability and the death, by the year 2020 in all age groups<sup>10</sup>. Acute subdural haematoma after trauma occurs during 14 days of injury and linked to higher rate of death with or without intervention of surgery<sup>11,12</sup>. In the comparison to another traumatic injury of the brain, degree of the underlying damage in brain linked to the more severity of acute subdural haematoma.<sup>13</sup> Its outcome depending on the ability to control ICP instead of removal of the subdural clot. Though clot removing timing within 4 hours of the injuries had a lower mortality rate as 30% and functional rate as; 65%, while ICP control has been a critical factor<sup>41</sup>. In this study cases were presented in an emergency within 30 minutes to 6 hours after trauma, their brain swelling was associated with acute subdural hematoma caused by secondary insult additionally to the injury of parenchyma. Consistently mostly authors would agree surgical cases should undergo evacuation immediately. This phenomenon was originally consistent on the findings of a study was carried out over 30 years ago

mentioned marked development of mortality if the SDH was evacuated within 4 hours of injury.<sup>10</sup> While few have since questioned this notion claiming either no difference in the outcome, or the poor outcome with the extra rapid time to evacuation<sup>12,15,16</sup>. Though the careful review of this series reveals that the cases those underwent immediate evacuation also having more severity of the neurologic injury prior to the surgery, and challenging the validity of the data outcomes.<sup>10,15,16</sup>

In this series, the Good functional outcome was found significantly associated with dural stabs as compare to open dural flap. Furthermore, age group of 21 to 40 years had a good outcome as compared to the age group of 41 to 60 years but it was non-significant. In the favor of this study many studies stated that an increased in favorable outcome significantly associated with younger cases.<sup>17</sup> Cases having age less than 40 years were found with 20% of mortality rate, as compared to those having age more than 40 years as rate of mortality 65%, while patients with age more than 80 years had mortality rate was very high as 88%.

As we found the good functional outcome in patients those underwent dural stabs as compare to those underwent open dural flap p-value 0.0005. In the comparison of this study Abdul Rashid et al,<sup>18</sup> reported that the outcome of case having early and open dural flap was seen poor, while dural-

stabs showed favourable outcome as 50% including 78.3% was survival rate and only 21.6% was mortality rate.

In this study it was observed that “conventional open dural flap surgery” to removing subdural clots in the occurrence of the coexisting edema and the injuries, even though early, leads to the poor outcome in the 67.6% cases. On another hand in a study reported that brain swelling and acute subdural hematoma were the commonest as 64% by findings of CT-scan,<sup>19</sup> even after decompression of surgery and acute subdural hematoma’s prognosis was still poor in the several patients. This is though due to coexisting damages of the brain “Diffuse Axonal Injury, contusions, lacerations” which leads to the poor outcome. Though the poor outcome is subsequent of microcirculation compression and resulting lower cerebrospinal fluid that leads to lucid interval i.e, “talk and die”.<sup>20</sup>

## Conclusion

It is concluded that the stabbing the dural stabs management showed better outcome underlying edematous brain slowly with better results as compare to open dural flap. More research is needed to conform these findings.

## References

1. Khalil IM, Sudumbrekar SM, Vadhanan S, Sengupta SK, Rappai TJ. Decompressive craniectomy in traumatic brain injury Rationale and practice. *Ind J Neurotrauma*. 2010;7(1):9-12.
2. Cooper DJ, Jeffrey VR, Lynnette M, Yaseen MA, Andrew RD, Paul D’U, et al. Decompressive craniectomy in diffuse traumatic brain injury. *N Engl J Med*. 2011 Apr 21;364:1493-502.
3. Stephen H, Kwok MH, Christopher RPL. What can be learned from the DECRA. *World Neurosurg*. 2013 Jan;79(1):159-61.
4. Ho KM, Honeybul S, Litton E. Delayed neurological recovery after decompressive craniectomy for severe nonpenetrating traumatic brain injury. *Crit Care Med*. 2011 Nov;39(11):2495-500.
5. Aarabi B, Hesdorffer DC, Ahn ES, Aresco C, Scalea TM, Eisenberg HM. Outcome following decompressive craniectomy for malignant swelling due to severe head injury. *J Neurosurg*. 2006;104(4):469-79.
6. Abdul RB, Mohammad AW, Altaf RK, Tariq R, Sajad A, Ramzan. Dural-Stabs after wide craniectomy to decompress acute subdural hematoma with severe traumatic brain edema- An alternative technique to open dural flap. *Ind J Neurotrauma*. 2010;7(1):29-36.
7. Rutland-Brown W, Langlois JA, Thomas KE, Xi YL. Incidence of traumatic brain injury in the United States, 2003. *J Head Trauma Rehabil*. 2006;21:544.
8. MacKenzie EJ. Epidemiology of injuries: Current trends and future challenges. *Epidemiol Rev*. 2000;22:112-9.
9. Marshall LF. Head injury: recent past, present, and future. *Neurosurgery*. 2000;47:546-561.
10. Murray CJ, Lopez AD. Global mortality, disability, and the contribution of risk factors: Global burden of disease study. *Lancet*. 1997;349:1436-12.
11. Bullock MR, Chesnut R, Ghajar J, Gordon D, Hartl R, Newell DW, et al. Surgical management of traumatic brain injury author G: surgical management of acute subdural hematomas. *Neurosurgery*. 2006;58:S16-24;discussion Si-iv.
12. Tallon JM, Ackroyd-Stolarz S, Karim SA, Clarke DB. The epidemiology of surgically treated acute subdural and epidural hematomas in patients with head injuries: A population-based study. *Can J Surg*. 2008;51:339-45.
13. Wilberger JE Jr, Harris M, Diamond DL. Acute subdural hematoma: Morbidity, mortality, and operative timing. *J Neurosurg*. 1991;74:212-8.
14. Wilberger JE, Harris M, Diamond DL. Acute subdural hematoma: morbidity, mortality and operative timing. *J Neurosurgery*. 1991;74(2):212-8.
15. Seelig JM, Becker DP, Miller JD, Greenberg RP, Ward JD, Choi SC: Traumatic acute subdural hematoma: major mortality reduction in comatose patients treated within four hours. *N Engl J Med*. 1981;304:1511-8.
16. Tien HC, Jung V, Pinto R, Mainprize T, Scales DC, Rizoli SB. Reducing time-to-treatment decreases mortality of trauma patients with acute subdural hematoma. *Ann Surg*. 2011;253:1178-83.
17. Servadei F. Prognostic factors in severely head injured adult patients with acute subdural haematoma's. *Acta Neurochir (Wien)*. 1997;139(4):279-85.
18. Bhatt AR, Wani MA, Kirmani AR, Raina T, Arif S, Ramzan A. Dural-stabs after wide craniectomy to decompress acute subdural hematoma with severe traumatic brain edema – an alternative technique to open dural flap. *Indian J Neurotrauma (IJNT)*. 2010;7(1):10.
19. Faleiro RM, Faleiro LC, Caetano E, Gomide I, Pita C, Coelho G, et al. Decompressive craniotomy: prognostic factors and complications in 89 patients. *Arq Neuropsiquiatr*. 2008;66(2b):369-73.
20. Schroder ML, Muizelaar JP, Kuta AJ. Documented reversal of global ischemia immediately after removal of an acute subdural hematoma: report of two cases. *J Neurosurg*. 1994;80:324-7.